



Ministry of Health & Family Welfare  
Government of India



## Training Manual on Eye Care for Medical Officer at Ayushman Bharat – Health and Wellness Centres





**Training Manual on Eye Care for Medical Officer**  
at Ayushman Bharat – Health and Wellness Centres

2021





# TABLE OF CONTENTS

List of Abbreviations		4
Chapter - 1	Introduction	5
Chapter - 2	Overview of Anatomy of Human Eye	7
Chapter - 3	Health Promotion in Eye Care	10
Chapter - 4	Examination of the Eye	13
Chapter - 5	Common Eye conditions - Eye Injuries	16
Chapter - 6	Common Eye conditions - Diminution of Vision	23
Chapter - 7	Common Eye conditions - Eyelids and Lacrimal system	31
Chapter - 8	Common Eye conditions - Conjunctival conditions	34
Chapter - 9	Common Eye conditions - Corneal Conditions, Uveitis	40
Chapter - 10	Common Eye conditions – Glaucoma	45
Chapter - 11	Eye conditions affecting Posterior Segment of Eye	48
Chapter - 12	Miscellaneous Eye conditions	53
Chapter - 13	Certification of Visual Impairment, Blindness	54
Chapter - 14	Eye Donation	56
Chapter - 15	Service Delivery Framework and Roles and Responsibilities of Medical Officer (AB-HWC-PHC/UPHC) in Eye Care	58
Chapter - 16	Clinical Scenarios	67
<b>ANNEXURES</b>		
Annexure - 1	Removal of superficial foreign bodies in the Eye	74
Annexure - 2	Eye Screening Tool to be used at Various Levels	75
Annexure - 3	How to apply Eye Drops correctly	77
Annexure - 4	How to apply Eye Ointment correctly	79
Annexure - 5	Community Based Assessment Checklist (CBAC)	80
Annexure - 6	Medicines and Diagnostics	83
Annexure - 7	Commonly used medicines for Eye Diseases	84
Annexure - 8	List of Equipment for Eye Care	85

## List of Abbreviations

AB-HWC	Ayushman Bharat- Health and Wellness Centre
AB-HWC-SHC	Ayushman Bharat- Health and Wellness Centre- Sub- Health Centre
AB-HWC-PHC	Ayushman Bharat- Health and Wellness Centre- Primary Health Centre
AB-HWC-UPHC	Ayushman Bharat- Health and Wellness Centre- Urban Primary Health Centre
AF	ASHA Facilitator
ANM	Auxiliary Nurse Midwife
ARMD	Age related macular degeneration
AWW	Anganwadi Worker
BP	Blood Pressure
CBAC	Community Based Assessment Checklist
CHO	Community Health Officer
CHC	Community Health Centre
CPHC	Comprehensive Primary Health Care
DH	District Hospital
DM	Diabetes Mellitus
DR	Diabetic Retinopathy
HIV	Human Immunodeficiency Virus
HMCF	Hand movement close to face
HSV	Herpes Simplex Virus
HTN	Hypertension
IEC	Information, Education and Communication
INR	International Normalized Ratio
IOL	Intra Ocular Lens
IOP	Intra Ocular Pressure
IU	International Unit
IV	Intravenous
KP	Keratic Precipitate
LE	Left Eye
MAS	Mahila Arogya Samiti
MO	Medical Officer
MPW	Multi-Purpose Worker
NAION	Non-arteritic ischemic optic neuropathy
NGO	Non-Governmental Organization
NPCB	National Programme for Control of Blindness
NPCB&VI	National Programme for Control of Blindness and Visual Impairment
NSAIDs	Nonsteroidal anti-inflammatory drugs
OA	Ophthalmic Assistant
OCT	Ocular coherence tomography
OPD	Out-Patient Department
RAAB	Rapid Assessment of Avoidable Blindness
RAPD	Relative afferent pupillary defect
RBSK	Rashtriya Bal Swasthya Karyakram
RE	Right Eye
ROP	Retinopathy of Prematurity
SDH	Sub-District Hospital
UHSND	Urban Health, Sanitation and Nutrition Day
VA	Vision Acuity
VC	Vision Centre
VHSND	Village Health, Sanitation and Nutrition Day
VHSNC	Village Health, Sanitation and Nutrition Committee
WHO	World Health Organization

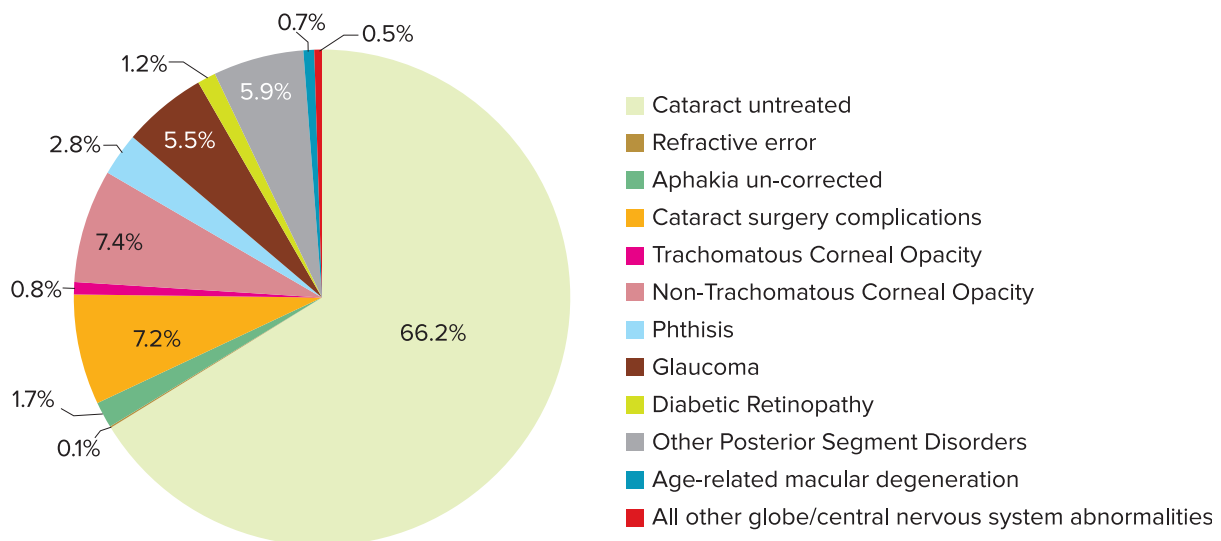
# CHAPTER - 1

## INTRODUCTION

India was the first country in the world to launch the National Programme for Control of Blindness (NPCB) in 1976 as a 100% centrally sponsored scheme (now 60:40 in all states and 90:10 in North-East States) with the goal of reducing the prevalence of blindness to 0.3% by 2020. The programme has been renamed in the year 2017 as National Programme for Control of Blindness and Visual Impairment (NPCB&VI). Rapid Survey on Avoidable Blindness conducted under NPCB during 2015-19 showed reduction in the prevalence of blindness from 1% (2006-07) to 0.36%. Apart from cataract surgeries, now the focus of the programme is on treatment and management of other eye diseases like glaucoma, diabetic retinopathy, vitreoretinal diseases, corneal blindness, low vision and childhood blindness. The programme is now geared to take care of all categories of visual impairment.

In 1999, the World Health Organization (WHO) launched Vision 2020: The Right to Sight to eliminate avoidable blindness by 2020. In 2013, World Health Assembly adopted Universal Eye Health: Global Action Plan 2014-19 with an aim to reduce prevalence of avoidable visual impairment by 25% by 2019 compared to the baseline prevalence at 2010.

### 1.1 What are the Problems of the Eye?



**Source- Causes of blindness in 2019 in population aged ≥ 50 years, National Blindness & Visual Impairment Survey India, 2015-2019- A Summary Report.**

India has around 4.9 million blind people and 32.9 million people with visual impairment (presuming population of India as 136 crores)<sup>1</sup>. Refractive error and Cataract are the most common causes of visual impairment in the country.

Estimated National Prevalence of Childhood Blindness is about 0.80 per thousand. India has implemented a series of measures in its ongoing NPCB&VI to combat blindness and visual impairment in the country.

With the introduction of Ayushman Bharat, an expanded package of services have been introduced at the Ayushman Bharat-Health and Wellness Centres (AB-HWC), which includes eye care provision at the level of AB-HWCs as part of the Comprehensive Primary Health Care (CPHC).

Most of the cases with eye problems will be referred to the nearest AB-HWCs in both rural and urban areas while high-risk cases will require referral to the Ophthalmic Assistant (OA) at Vision Centres (wherever available) and to the Eye specialist/Eye doctor at the Community Health Centre (CHC)/Sub-District Hospital (SDH)/District Hospital (DH) or other higher health facilities for complete diagnosis and treatment.

In the rural areas, the Community Health Officer (CHO) present at the Ayushman Bharat- Health and Wellness Centre- Sub- Health Centre (AB-HWC-SHC) will be responsible for making referral to you, heading the Ayushman Bharat- Health and Wellness Centre- Primary Health Centre (AB-HWC-PHC). In some cases, the CHO may undertake referrals to higher health facilities (all the referrals undertaken will be in consultation with you, the Medical Officer).

In the urban areas, you, the Medical Officer heading the Ayushman Bharat- Health and Wellness Centre- Urban Primary Health Centre (AB-HWC-UPHC) will be responsible for making all referrals.

The Staff Nurse, at AB-HWCs will assist you in making arrangements for the referral.

You will continue to provide support to ASHA, ASHA Facilitators (AFs), Multi-Purpose Worker/ Auxiliary Nurse Midwife (MPW/ANM), CHO, Staff Nurse at AB-HWCs in undertaking their tasks. You will monitor, support and supervise them in delivery of Eye Care services to the community in your area.

This Training Manual builds on your existing knowledge and skills by providing you with new information and skills.

**This Training Manual has the following content:**

1. Overview of Anatomy of Human Eye.
2. Health Promotion in Eye Care.
3. Examination of the Eye.
4. Overview and management of Common Eye Conditions at Primary Care Level.
5. Service Delivery Framework and Roles and Responsibilities of Medical Officer (MO) in Eye Care.

---

<sup>1</sup> National Blindness Survey- The Rapid Assessment of Avoidable Blindness (RAAB) survey India- 2015-2019.

# CHAPTER - 2

## OVERVIEW OF ANATOMY OF HUMAN EYE

The human eye is a slightly asymmetric sphere with an approximate sagittal diameter (length) of about 24 to 25 mm and a transverse diameter of 24 mm. It has a volume of about 6.5 cc.

The Eye has:

### **Three different layers-**

- The external layer, formed by the sclera and cornea.
- The intermediate layer, divided into two parts: anterior (iris & ciliary body) & posterior (choroid).
- The internal layer, or the sensory part of the eye, the retina.

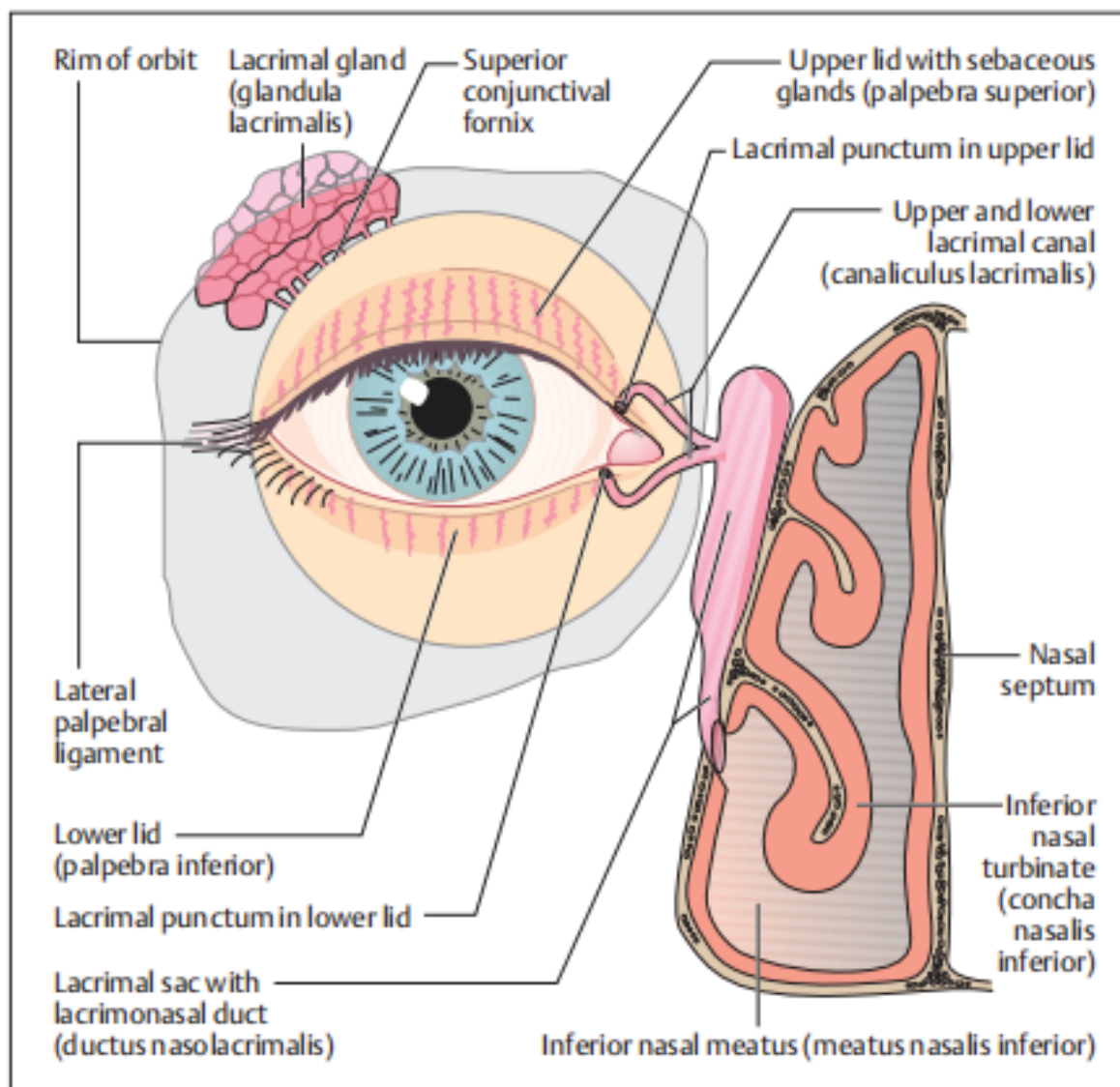
### **Three chambers of fluid-**

- Anterior chamber (between cornea and iris),
- Posterior chamber (between iris, zonule fibers and lens), &
- The vitreous chamber (between the lens and the retina).

The first two chambers are filled with aqueous humor, whereas the vitreous chamber is filled with a more viscous fluid, the vitreous humor.

On simple inspection of the eye, the following can be easily seen:

**Eyelids and Lacrimal Apparatus-** Upper and lower eye lids with eyelashes emanating from them and opening of Meibomian glands near posterior lid margins can be seen. At medial canthus, a punctum on both lid margins can be seen, through which tears are drained into nose via the Nasolacrimal Duct. The capillary action of a sharply apposed, lower lid margin helps in drainage of tears.



### Lacrimal Apparatus

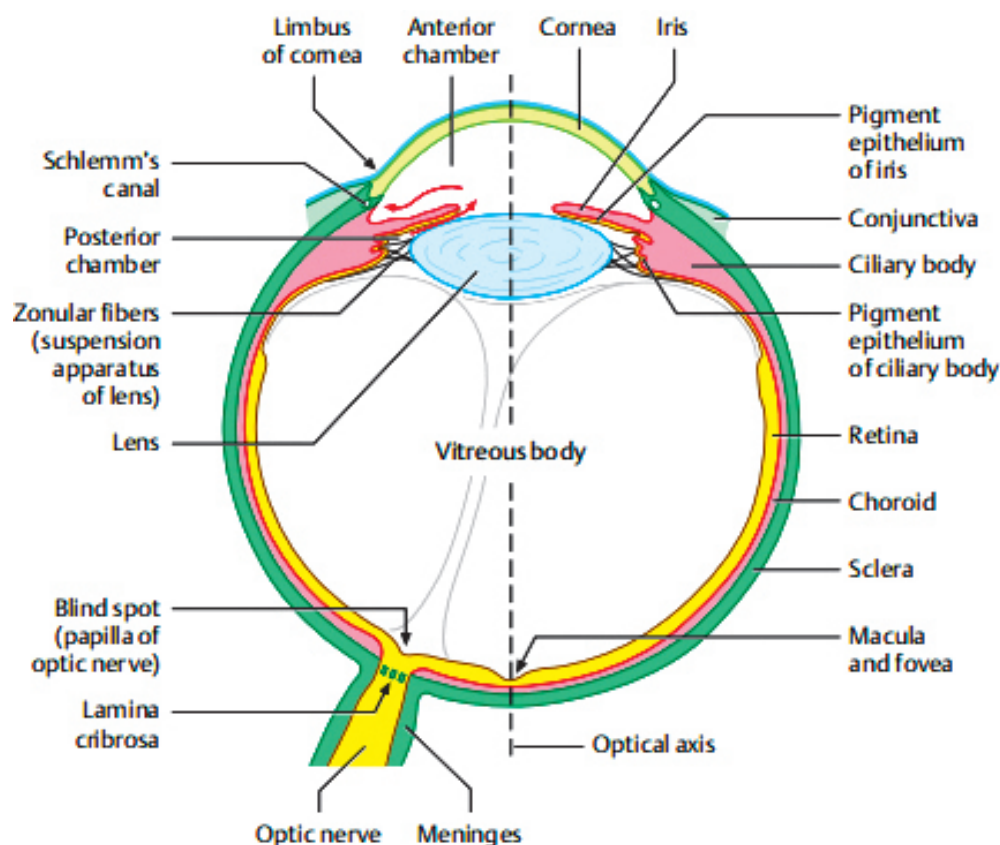
Source- Faller A, Schünke M, Schünke G. 2004. *The Human Body An Introduction to Structure and Function*. Page 642, Chapter 15, Sense Organs, Figure 10: The lacrimal apparatus. Thieme Stuttgart, New York.

The “white of the eye”, the **sclera**, forms part of the supporting wall of the eyeball. The sclera is continuous with the cornea. This external covering of the eye is in continuity with the dura of the central nervous system. A transparent external surface, the **cornea**, sits like a dome in anterior 1/5th of the globe. The pupil and the iris can be seen through the Cornea. This is the first and most powerful lens of the optical system of the eye and allows, together with the crystalline lens, the production of a sharp image at the retinal photoreceptor level.

A black-looking aperture, the **pupil**, allows light to enter the eye. Pupil is a central aperture in the coloured circular muscle, the **iris**, which is pigmented and gives us our eye color. This circular muscle (Iris) controls the size of the pupil so that more or less light, depending on conditions, is allowed to enter the eye.

The **lens** is a transparent body located behind the **iris**. It is suspended by ligaments (called zonule fibers) attached to the anterior portion of the ciliary body. The contraction or relaxation of these ligaments, as a consequence of ciliary muscle actions, changes the shape of the lens, a process called **accommodation** that allows to form a sharp image on the retina.





### Horizontal section of eyeball

Source- Faller A, Schünke M, Schünke G. 2004. *The Human Body An Introduction to Structure and Function*. Page 626, Chapter 15, Sense Organs, Figure 1: Horizontal section through the eyeball. Thieme Stuttgart, New York.

Light rays are focused through the transparent cornea and lens upon the retina. The central point for image focus (the visual axis) in the human retina is the **fovea**. Here a maximally focused image initiates resolution of the finest detail and direct transmission of that detail to the brain for the higher operations needed for perception. The optic axis is slightly closer to the nasal area and projects closer to the optic nerve head. The optic axis is the longest sagittal distance between the front or vertex of the cornea and the furthest posterior part of the eyeball. The eye is rotated around the optic axis by the extraocular muscles.

Each eyeball is held in position in the orbital cavity by various ligaments, muscles, and fascial expansions that surround it. Three pairs of muscles (six muscles altogether) called Extra Ocular Muscles are inserted into the sclera. Two pairs of recti muscles run straight to the bony orbit of the skull, and are orthogonal to each other (the superior rectus, the inferior rectus, the lateral rectus, and the medial rectus muscles). Another pair of muscles are the oblique muscles (superior oblique and inferior oblique). These extraocular muscles, in coordination, rotate the eyeball in the orbits and allow the image to be focused, at all times, on the fovea of the central retina.

## CHAPTER - 3

# HEALTH PROMOTION IN EYE CARE

The eyes are extremely delicate part of the body and hence need good care. This care begins at birth and continues through the life span. Health promotion activities at the Ayushman Bharat- Health and Wellness Centre- Primary Health Centre and Urban Primary Health Centre (AB-HWC-PHC/UPHC) will include regular awareness sessions on care of the eye, identification of common eye related symptoms and importance of seeking treatment early. For those suffering from blindness, health promotion activities will be centered on rehabilitation, regular check-ups and reintegrating the person into the community.

### 3.1 Key health promotion messages for patients for good Eye Health

- a. If you have an eye problem, go to your nearest health care facility as soon as possible. Go immediately if you have an eye injury, if your eyes are painful or if your vision suddenly becomes poor.
- b. Do not put any medication into your eyes unless prescribed by a health care provider.
- c. Protect your eyes from excessive sunlight with, for example, hats, scarves, sunglasses or umbrellas.
- d. If you have diabetes, have a complete eye examination including a Retinal Examination at least once a year, and check your blood sugar regularly.
- e. If you have a relative with glaucoma or if you are above 40 years of age, have an eye examination for glaucoma at least once a year.
- f. Use protective eyewear when working with objects/in professions that might damage your eyes: welding, chemicals, blast furnaces, metal or wood projectiles, threshing of crops, etc.
- g. If chemicals, or substances that burn or sting, come into contact/fall into your eye, immediately rinse your eye with clean water for at least 15 minutes.
- h. If you have problems seeing small nearby/far objects or when reading, you may need glasses for near/far work.
- i. Do not read in poor lighting conditions. Use glasses if needed and as prescribed by an Eye Doctor/Eye Specialist.

### 3.2 General health messages which also impact Eye Health

- a. While driving/travelling, wear a seat belt so injuries are avoided to both the body as well as the eyes. Those driving two wheelers, must wear helmets covered with the front glass.
- b. Keep hands and faces clean to avoid infections, including eye infections.
- c. Protect your health, including your eye health, by not smoking or not consuming tobacco.



### 3.3 Messages for mothers and caregivers for their children

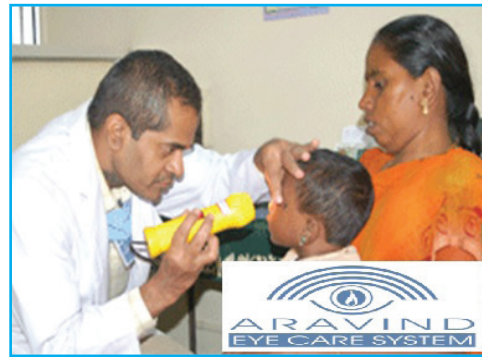- a. Clean their eyes immediately after birth and if available, ASHA will teach the mother/caregivers and provide eye care to the newborn, if required by use of an eye ointment.
- b. A baby with eye discharge needs treatment immediately; inform them to seek help from the nearest health facility.
- c. The retina of all preterm infants or low birth weight babies should be screened for any Retinopathy of Prematurity (ROP) by an Ophthalmologist within 30 days of birth.
- d. Make sure all mothers/caregivers to report if their child is not looking at them, or does not respond to visual stimuli after age of 6 weeks, or not looking straight. Mobilize the mother/caregivers for screening of children for eye care by Rashtriya Bal Swasthya Karyakram (RBSK) team/ or by an Ophthalmic assistant.
- e. Children should not play with or near sharp objects to avoid eye injuries.
- f. Avoid applying 'kajal' or 'surma' in the eyes of the children.
- g. Promote early and exclusive breastfeeding for six months.
- h. Mothers and children should be fully immunized including against rubella and measles.
- i. Regular vitamin A supplementation of pre-school children from age of 9 months is important for good vision and healthy growth.
- j. Children should eat foods rich in Vitamin A to keep their eyes healthy.
- k. Children should be made secure while travelling by taking all possible preventive measures of having eye injuries e.g. seat belts, helmets, etc.

### 3.4 Simple Eye Care messages in Eye Health Promotion

Infections of the eye spread very rapidly, if proper care is not taken. Ways to maintain eye health are as follows:

1. Keep eyes clean by washing them with clean water. Washing eyes at bedtime is very good as it removes the dirt and dust collected throughout the day.
2. Do not work in poor light. Reading in poor light can strain eyes.
3. Always use a clean cloth to wipe eyes. Do not use saris, dhotis, or sleeves of clothes to wipe eyes. These may cause serious infection in the eyes. Eye diseases such as conjunctivitis and trachoma spread by this way.
4. Each person should use a separate cloth, towel or handkerchief for wiping eyes. If one eye is already infected, use a separate clean cloth for each eye.
5. Avoid the glare. Do not stare at the sun and other bright objects.
6. Never walk out in the sun without sunglasses.
7. Eat a diet rich in Vitamin A and appropriate breastfeeding by mothers (colostrum is rich in Vitamin A).
8. Do follow the 20-20-20 rule of eye care when using a computer/laptop, mobile phone, or watching television. Every 20 minutes, refocus your eyes for 20 seconds to an object located at least 20 feet away.
9. Report any eye infection to a health worker. Do not use home remedies for eye medication. Do not use medicines given by road-side medicine sellers. These may not help and may even cause blindness.

10. Eye drops and eye ointment only provided by a Medical doctor should be used. Do not use any eye medicine without any medical prescription.
11. Do not use eye drops prescribed for someone else in the family. Once eye drops are opened, they should not be used beyond one month.
12. Never use eye drops without prescription as these may contain steroids which are harmful for the eyes.
13. Educate community members to pay special attention in using the eye drops. They might not make the difference between eye drops and ear drops and can put visiting of the ear into their eyes.
14. Patient with eye infection should avoid going in swimming pools and visiting public places.



*Eye Testing*  
Source: Aravind Eye Hospital, Madurai



*Checking Distant vision in the community*  
Source: Dr. Rajendra Prasad Centre for Ophthalmic Sciences



*Community Awareness on Eye Care*  
Source: Dr. Rajendra Prasad Centre for Ophthalmic Sciences

# CHAPTER - 4

## EXAMINATION OF THE EYE

At the AB-HWC-PHC/UPHC level, the MOs can identify commonly preventable diseases by listening to the patient's symptoms and looking for common eye signs by a simple torch light examination.

### 4.1 Most common Eye Complaints:

1. Diminution/Cloudiness of Vision- may be sudden or insidious, can be painless or painful, for near or distant objects.
2. Redness of the eyes – can be a sign of infection, allergy or a foreign body in the eye.
3. Watering and/or discharge from the Eye.
4. Painless or painful swelling on lids or around lids – Indicates infection of lids/eyes.
5. Foreign body sensation/grittiness/itching in the eye.
6. Headache/Glare/ Photophobia/ seeing coloured halos around light bulb.
7. History of foreign body falling in eye-chemicals, wood splinters, metal, etc.
8. Diplopia (Double Vision) or Polyopia.
9. Bulging (Proptosis) of eyes or obliqueness of eyes (squint).
10. White reflex in the pupillary area.



*Examination of the Eye  
Source- Aravind Eye Hospital, Madurai*

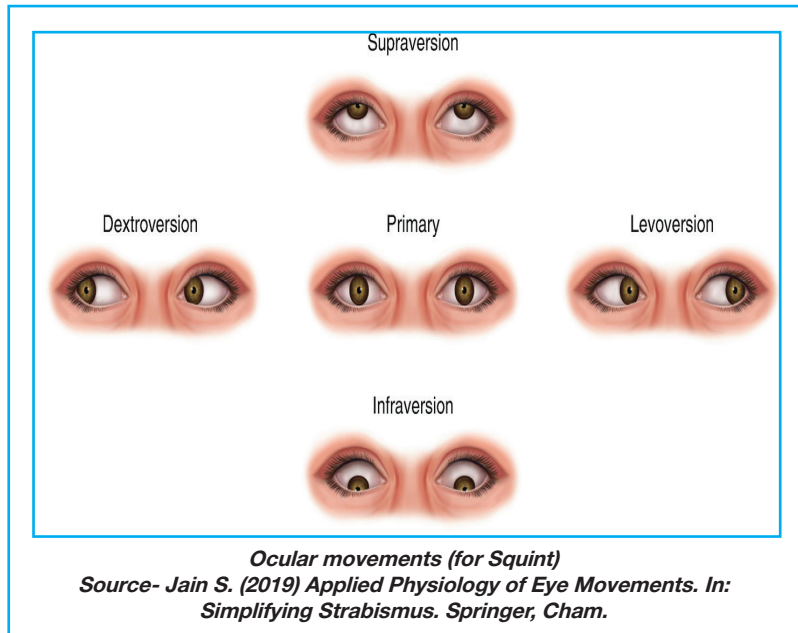
### 4.2 History to be elicited/ asked:

- Duration and progression of symptoms,
- Changes in vision (decreased vision),
- Foreign body sensation in the eye,
- Associated pain and photophobia,
- History of trauma - where, when, injuring object,
- Eye discharge/ watering - degree, amount and nature,
- Any Systemic Complaints including History of Diabetes, Hypertension, etc.
- Any recent eye surgery.

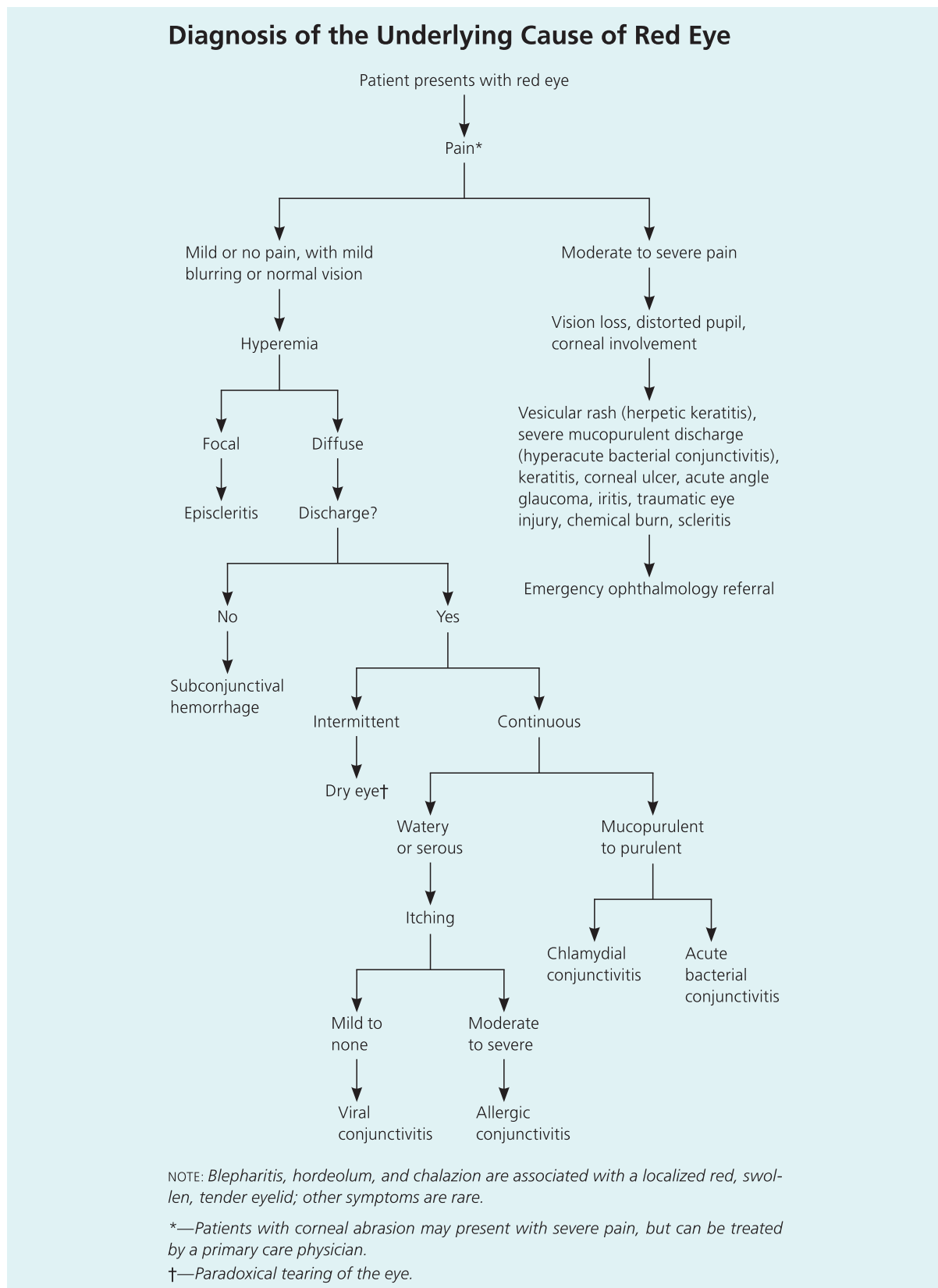


### 4.3 Examination to be done: You should use a well-focused torch light

- Explain to the patient what are you going to do.
- Get Vision checked for distance and near (35 cms) and record it with glasses and/ or contact lenses, if patient is wearing one.
- Examine Eyelids for Drooping (Ptosis), Swelling in and around eyelids, injury, inflammation, Trichiasis (In-turning of Eye Lashes), entropion/ ectropion, follicles, etc.
- Presence of any Squint. Check Ocular movements in all directions.
- Check for foreign bodies - if superficial, remove. The upper lid should be everted to look for foreign bodies, follicles, concretions, masses, etc.
- Conjunctiva should be seen for any redness, discharge, hemorrhage, etc. The type of redness and discharge can give a clue to diagnosis of underlying pathology.
- Cornea examination - If it is clear, shiny and transparent or not. Any foreign body, ulceration or dryness etc. should be noted.
- The Anterior Chamber depth (shallow or deep) should be noted and presence of hypopyon (Pus)/ hyphema (Blood) and or keratic precipitates (round opacities at back of cornea) may be noted.
- Pupils - whether round, equal in size, and reactive to light (Any afferent pupillary defect points to a posterior segment or neurological deficit).
- The Crystalline lens can be seen through the pupil. Any white, greyish white reflex denotes a Cataract or some posterior segment pathology.
- Do a regurgitation test for patency of Lacrimal apparatus, especially in elderly patients (press on the medial side of inner canthus).
- Intraocular pressure measurement (even digital palpation over the upper lid can give a rough estimate of raised Intra Ocular Pressure -IOP).
- Any other relevant examination depending upon patient's presentation.
- If an Ophthalmic Assistant (OA) is available in the centre, his help can be taken for all these examinations.



Common causes of red eye and their clinical presentations are summarized in figure/ flowchart below.



### Red Eye Flow Diagram

**Source-** Cronau H, Kankanala RR, Mauger T. *Diagnosis and management of red eye in primary care. Am Fam Physician.* 2010 Jan 15;81(2):137-44. PMID: 20082509.

## CHAPTER - 5

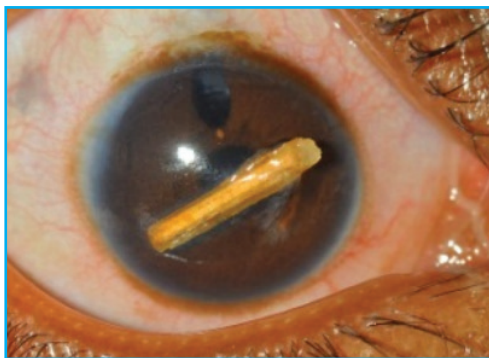
# COMMON EYE CONDITIONS - EYE INJURIES

Injuries to the eye are common. Many are minor but, if not treated quickly and appropriately, can lead to sight-threatening complications. Some traumatic eye injuries are severe, and even with expert management vision/ sight may not be salvaged. The majority of eye injuries occur in young people and traumatic chemical exposure commonly occurs at home, work and in association with criminal assaults.

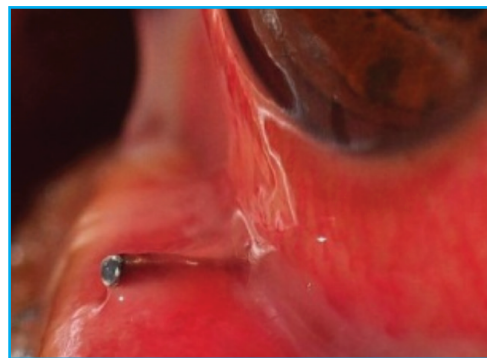
### Prevention of blindness from eye injuries requires:

- injury prevention (health promotion including advocacy),
- early presentation by the patient (health promotion and health worker training),
- accurate assessment (good primary eye care and first aid),
- prompt referral of serious injuries requiring specialist management.

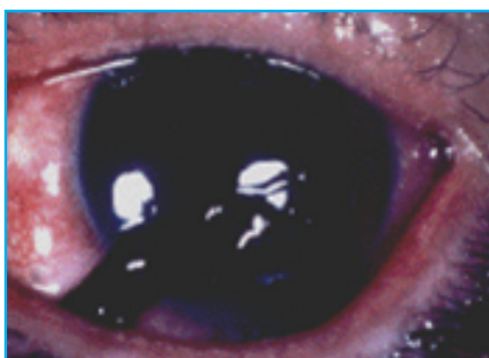
Traumatic eye injuries are one of the common causes of monocular blindness. These injuries have an important socioeconomic impact both in healthcare costs and lost productivity at the workplace. In the prehospital/ primary care settings, the most important management principle is to protect the eye from further trauma during transport.



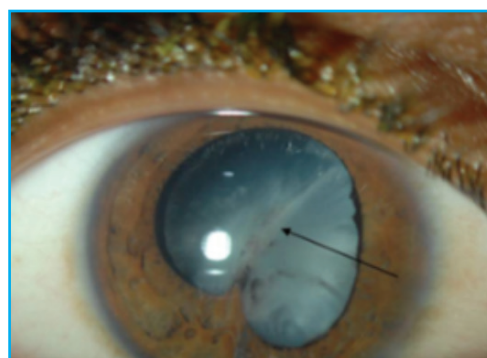
*Foreign body (Penetrating injuries)*



*Perforating injury*

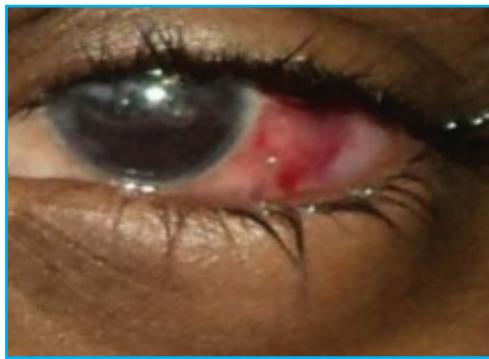


*Globe Rupture*

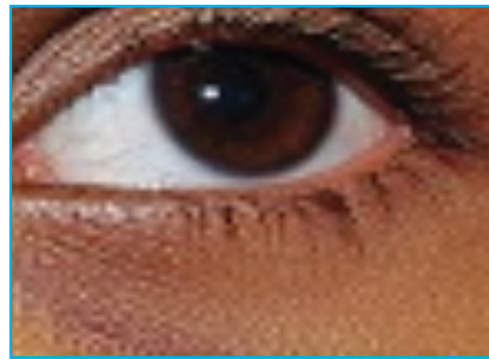

*Traumatic cataract (blunt injuries)*

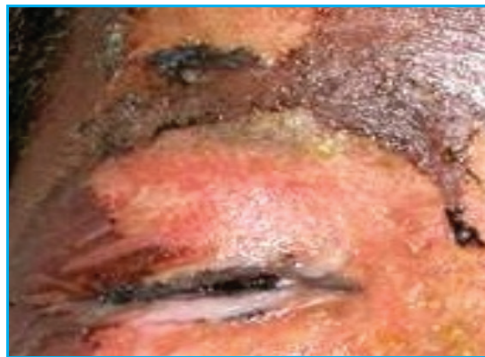*Source- Aravind Eye Hospital, Madurai*



*Sports - Superficial injuries*



*Thermal accidents*



*Blow out fractures*

*Source- Aravind Eye Hospital, Madurai*

## 5.1 Penetrating injury to sclera/ cornea (Open globe injuries)

These injuries are often caused by sharp objects flying at speed in the eye either through cornea or sclera. Sometimes open globe injury could be due to blunt trauma also, where blunt trauma causes very high pressure built up in the affected eyeball leading to the rupture of cornea or sclera.

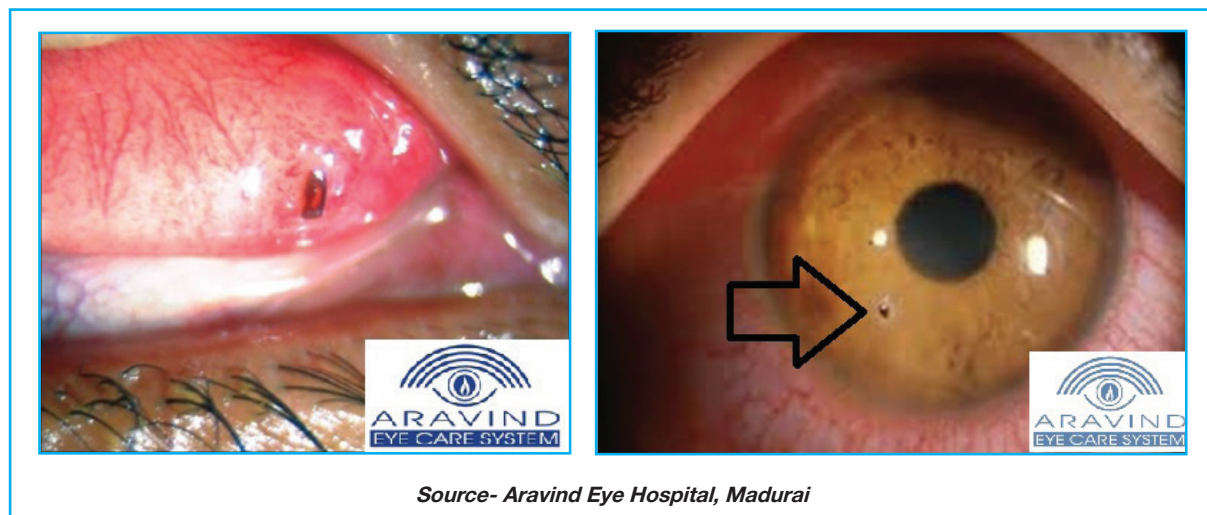
**What to look for:** There is likely to be history of severe eye pain, decreased vision, and on examination hyphema (blood in the anterior chamber), a “peaked” or teardrop-shaped pupil, and extrusion of globe contents can be seen. However, many patients may not display these classic findings and it is important to have high clinical suspicion of an open globe injury whenever a patient has the possibility of a penetrating eye injury or has sustained major blunt force to the face.

### What to do: Urgent referral.

**Before referral management:** The goal of management for open globe injuries at primary care settings is to avoid secondary eye injury/ damage by preventing any increase in intra-ocular pressure (IOP).

- Application of any external pressure to the eye must be avoided.
- Put a protective eye shield over the affected eye for eye protection during transportation.
- Do not to place any pressure points of the protective eye shield onto the eye itself, but place the pressure points instead onto the bones surrounding the eye.
- If a metal or plastic eye shield is not available, a Styrofoam or plastic cup should be taped over the eye for protection.
- The head of the bed should be elevated if possible, to prevent increased IOP.
- Give tetanus toxoid injection.
- As pain, agitation, uncontrolled hypertension and Valsalva maneuvers can elevate IOP, appropriate analgesic, antiemetic and sedative therapy should be provided before referral.

## 5.2 Foreign Body in Conjunctiva/ Cornea



### 5.2.1 Retained Foreign Body in the eye

It is usually associated with an open globe injury (as seen above) and the injuring object or part of it may get lodged and retained in the eye. The sign and symptoms will be like that of open globe injury as mentioned above. The foreign object may or may not be visible on examination in primary care settings.

**What to do: Urgent referral.** Transport the patient to appropriate facility after providing the first aid as done in the open globe injury as soon as possible - eye shield for protection, raising the head of the bed and giving medications to reduce/ ameliorate pain and vomiting.

Do not attempt to remove intraocular foreign bodies except those are on the conjunctival or outer corneal surface. The distal end of an intraocular foreign body may be lodged deep within the eye, manipulation of the object can increase the severity of injury by further damaging surrounding structures and will enhance anxiety and/or agitation in the patient.



Give tetanus toxoid injection. Prognosis of penetrating eye injuries is usually poor which should be communicated to the patient and his/her relatives.

Refer to Annexure-1, regarding Steps in removal of superficial foreign bodies in the eye.

### 5.3 Traumatic Hyphema

Although relatively minor direct blunt eye trauma can cause a hyphema, most are caused by major blunt force and over 80% of patients with traumatic hyphemas have concomitant injuries, such as facial fractures and open globe injuries.

**What to look for:** History of diminished vision which may have improved gradually over time, red-tinged vision, photophobia after the traumatic event - blunt or penetrating.

Look for concomitant facial injuries like facial fractures and open globe injuries including retained foreign body in the eye. On eye examination sliver of red discoloration inferior to the patient's pupil may be seen.

**What to do:** Observe all the open globe precautions in a patient with a traumatic hyphema. Avoid giving Nonsteroidal anti-inflammatory drugs (NSAIDs) for relieving pain and other antiplatelet agents and give cycloplegic medications (atropine 1%, homatropine 2%, and tropicamide 1%) to minimize repeated constriction and dilation of the iris or make the patient stay in a dark room. Refer the patient to an Ophthalmologist immediately.

### 5.4 Retrobulbar Hematoma

**What to look for:** Typical signs and symptoms like decreased Visual Acuity (VA), painful proptosis (anterior displacement of the eye), a dilated pupil and restricted extraocular movements. Symptoms usually develop over a period of time (few minutes to hours) as the expanding hemorrhage exerts increasing pressure on the eye, resulting in elevated IOP. Elevated IOP results in retinal & optic nerve ischemia which may result in permanent loss of vision.

**What to do:** Transfer the patient immediately to the appropriate facility. Give anti-emetic as vomiting may increase IOP and painkillers. Avoid NSAIDs and anti-platelet agents.

### 5.5 Chemical burns

**What to look for:** History of severe pain in the affected eye/s, decreased vision, blepharospasm (inability to open the eyelids) and watery eyes. However, exposure to some alkali substances may not be painful at first due to the local inhibition of sensation. In severe cases of alkali injury, the eye may appear white due to conjunctival ischemia or a large cornea defect may be visible.

**Table 1: Some of the chemicals found in common household/ industrial items**

Chemical	Product	Common items
Acids	Sulphuric acid	Toilet cleaner, Industrial cleaner battery fluid
	Sodium hypochlorite	Pool cleaners, bleach
	Acetic acid	Vinegar
	Hydrofluoric acid	Glass polishers, rust removal agents
	Hydrochloric acid	Food and leather processing agents
Alkali	Calcium carbonate / Magnesium carbonate	Lime (building material) - plastic, mortar, cement, whitewash
	Calcium hydroxide	Plaster, mortar
	Sodium hydroxide / Potassium hydroxide	Oven and drain cleaner
	Magnesium hydroxide	Fireworks
	Ammonium hydroxide	Ammonia (cleaning agents, fertilizers, refrigerants)
	Sodium tripolyphosphate	Dishwasher detergent

**What to do:**

- Examine the eye quickly and remove any particulate matter with a moist cotton swab.
- Do **immediate and copious irrigation with clean water** of the eye to dilute and remove as much of the chemical as possible.
  - ▶ Irrigation should begin as soon as the patient is seen - whether in community settings or at the AB-HWCs or at any other facility.
  - ▶ The patient should be made to lie on his/her side with the affected eye being downwards.
  - ▶ Irrigation using Normal saline/ lactated Ringer's or distilled water should be directed from the nasal corner outward to wash away chemicals from the lacrimal punctum towards the lateral canthus.
  - ▶ If these solutions are not available clean tap water for irrigation can be used.
  - ▶ Irrigation can be done through intravenous (IV) cannula or nasal cannula tubing into the affected eye. The upper lid needs to be everted and copiously irrigated with clean water specially in cases of lime/chuna falling in the eye.
  - ▶ During the irrigation patient must be directed to look in all directions so that complete removal of chemicals from all the surface of the eye is ensured.
- Attempt should be made to identify the chemical in question and mention this information on referral slip or telephonically.
- All patients with chemical eye burns should be referred and transported to the appropriate health centre immediately with ophthalmologist after initial irrigation (irrigation may be continued during transportation) and giving pain killer through injection.

## 5.6 Thermal Ocular injuries

These are usually sustained as a result of falling into fires or being splashed by hot fluids like boiling water or oil. They can also be sustained from cigarettes and other hot objects.

### What to do:

Treat these injuries as chemical injuries are treated. However, irrigation is not required. Apply antibiotic ointment into the eye, and then cover them with a moist sterile dressing. Refer to higher health facilities with an Ophthalmologist.

## 5.7 Ultraviolet Keratitis (Actinic Keratitis)

Ultraviolet burns of the cornea are usually caused by use of a sunlamp without eye protection, exposure to a welding arc, or exposure to the sun when on snow e.g., skiing ("snow blindness").

**Clinical presentation:** There are no immediate symptoms, but about 6-12 hours later the patient complains of agonizing pain and severe photophobia. Slit-lamp examination after instillation of sterile fluorescein shows diffuse punctate staining of both corneas.

**Treatment** consists of binocular patching and instillation of 1-2 drops of 1% cyclopentolate (to relieve the discomfort of ciliary spasm). All patients recover within 24-48 hours without complications. Local anesthetics should not be prescribed because they delay corneal epithelial healing.

## 5.8 Lid injuries/lacerations:

They can result from accidents, blunt or penetrating trauma.

### What to do:

**For minor scratches or small cuts:** These wounds should be cleaned, antiseptic solution applied and suturing done. Oral antibiotics should be considered.

**For other injuries:** Look for the injuries to the globe (eye ball). Assess the degree and extend of injuries especially look for canalicular damage and manage/ provide first aid for any injuries to the globe as mentioned above. If the injuries are due to animal bite/ scratch, give injection Rabivpur 0.1ml intradermal (0.5ml Intramuscular) at 2 sites on the day of presentation, give injection tetanus toxoid 0.5ml and also give human anti-rabies serum @20 International Unit (IU)/ Kg locally. Refer to appropriate facility for management after cleaning the wound thoroughly and remove foreign bodies if any. Ask the patient to come back for follow up care and completion of Rabivpur course. Oral antibiotics can also be added.

**Table 2: Ocular signs and their implications following ocular trauma**

Structure	Appearance and associated features	Implications
Lids	Lacerations of lid margins Puncture wounds Involvement of medial canthus	Will require accurate repair Check for globe perforation Check for canalicular damage
Conjunctiva	Sub-conjunctival haemorrhage	Usually harmless, but exclude perforation if the IOP is low
Sclera	Grey or brown discoloration on sclera	Check for scleral perforation or laceration
Cornea	Foreign body Abrasion Multiple staining areas following arc welding Laceration with iris prolapse	Remove foreign body Treat with antibiotic and pad Treat as for an abrasion Will require urgent repair
Anterior chamber	Blood in the anterior chamber – hyphaema	Usually resolves with conservative treatment; if secondary glaucoma, lower IOP with medicines
Pupil	Peaked  D shaped – Iris dialysis	Check for laceration with iris prolapse, and refer for abscission repair  Manage conservatively but watch for secondary glaucoma
Lens	Iris tremor – probable lens dislocation White lens	Usually requires removal  Lens damaged resulting in a cataract
Red reflex	No or poor red reflex	Possible vitreous haemorrhage
Proptosis	Swollen lids and protruding eye	Medial wall blow out fracture with air in the orbit, orbital contusion or sub-periosteal haematoma
Enophthalmos	Eye looks smaller – sunken-in globe	Inferior wall blow-out fracture

Any patient with retained foreign body, penetrating or globe trauma need to be referred immediately to a Tertiary care Centre, after covering eye with an eye shield and if needed a tetanus shot can be given.

**NEVER ATTEMPT TO REMOVE A RETAINED FOREIGN BODY IN A PENETRATING EYE INJURY.**

## CHAPTER - 6

# COMMON EYE CONDITIONS - DIMINUTION OF VISION

### 6.1 Acute vision loss in one eye (monocular vision loss):

#### **Approach to acute monocular loss of vision:**

Ask the patient about the affected eye, whether vision loss is painful or painless, peripheral, central or sectoral. Onset and progression of the loss of vision over time should be documented. In patients with optic neuritis it may quickly evolve and then subsequently improve; in ischemic optic neuropathy it may be sudden and fairly static; in patients with compressive lesions, it may seem to be sudden in onset, but its occurrence is more likely to be insidious and slowly progressive.

Assess visual acuity and do visual field measurement. If the vision improves significantly with pinhole it may be due to refractive errors. Corneal or lens abnormalities may lead to refractory errors. If it does not improve with pinhole consider retinal or optic nerve diseases.

Retinal causes often spare colour vision, are painless and cause central vision loss. On the other hand, in optic neuropathy, colour vision is often affected, may be painful and field loss can be variable. Monocular metamorphopsia (wavy, warped images) and appearance of flashing or colored lights often points towards retinal lesion. Conversely, visual blurring with a description that colors look “washed out” or “faded” may suggest optic nerve dysfunction.

It is also important to elicit the presence or absence of associated orbital, neurologic, or systemic symptoms. The quality and severity of pain should be characterized; pain is typically present in disorders such as optic neuritis or giant cell arteritis, but is absent in most retinal diseases or non-arteritic ischemic optic neuropathy.

Knowledge of a patient’s age and medical history, in particular a history of vascular risk factors, cancer, or autoimmune disorders, is essential in establishing a reasonable differential diagnosis.

The hallmark of a unilateral optic neuropathy is the relative afferent pupillary defect (RAPD). The RAPD is determined by the swinging flashlight test, during which light is alternately directed toward each pupil. When light is directed toward the unaffected eye, both pupils should constrict normally. When light is shined into the affected eye, the dilation of both pupils indicates the presence of a RAPD.

For traumatic eye injuries leading to acute loss of vision in one or both eyes, see Chapter- 5.

**Table 3: Etiology of acute monocular vision loss and their characteristics findings**

Etiologies of retinal diseases	Examination and Fundus findings
Central Retinal Artery Occlusion	Retinal whitening, Cherry red spot
Branch Retinal Artery Occlusion	Segmental retinal whitening
Retinal Vein Occlusion	Retinal haemorrhages and engorged vein
Retinal detachment	Billowing, elevated retina
Central serous retinopathy	Macular subretinal fluid, Ocular coherence tomography (OCT) confirmatory
Cystoid Macular Edema	Subtle macular elevation, OCT confirmatory
Acute idiopathic blind spot enlargement syndrome and multiple evanescent white dot syndrome	Photopsia, blind spot enlargement, subtle peripapillary retinal changes may be seen
Etiologies of optic neuropathy	Typical clinical features and Fundus findings
Optic neuritis	Pain on eye movement, Normal appearing optic nerve or mild swelling, worst symptoms at about 7-8 days, Spontaneous recovery,
Non-arteritic ischaemic optic neuropathy	Painless, Altitudinal visual field deficits, optical disc edema (may be sectoral), small cup:disc ratio, Risk factors - age, vascular risk factors, nocturnal hypotension
Arteritic ischaemic optic neuropathy	Systematic symptoms (myalgias, jaw claudication, fever, scalp tenderness, weight loss), optic disc edema (with or without cotton wool spots), increasing age is a risk factor
Inflammatory	Maybe associated with uveitis, systematic inflammatory symptoms
Infections	'Neuroretinitis' macular star occasionally
Hereditary conditions (Leber hereditary optic neuropathy)	Painless sequential visual loss, young men typically affected, Pseudo swelling of optic disc, Peripapillary telangiectasias

**Note :**

**Any patient with Sudden painless or painful loss/ dimness of Vision whether associated with Trauma or not, is an ocular emergency and needs immediate referral to a Tertiary level Ophthalmic Facility.**

## 6.2 Gradual Diminished vision in either one or both eyes:

Patients with gradual loss of vision present with chronic, slowly progressive loss of vision which is generally painless. Visual loss is usually bilateral, but may occur asymmetrically, and happens over weeks to years. Poor vision in one eye may only be noticed when the patient closes the other eye, and thus may be reported to be sudden in onset in some cases.

**Table 4: Common causes of gradual loss of vision**

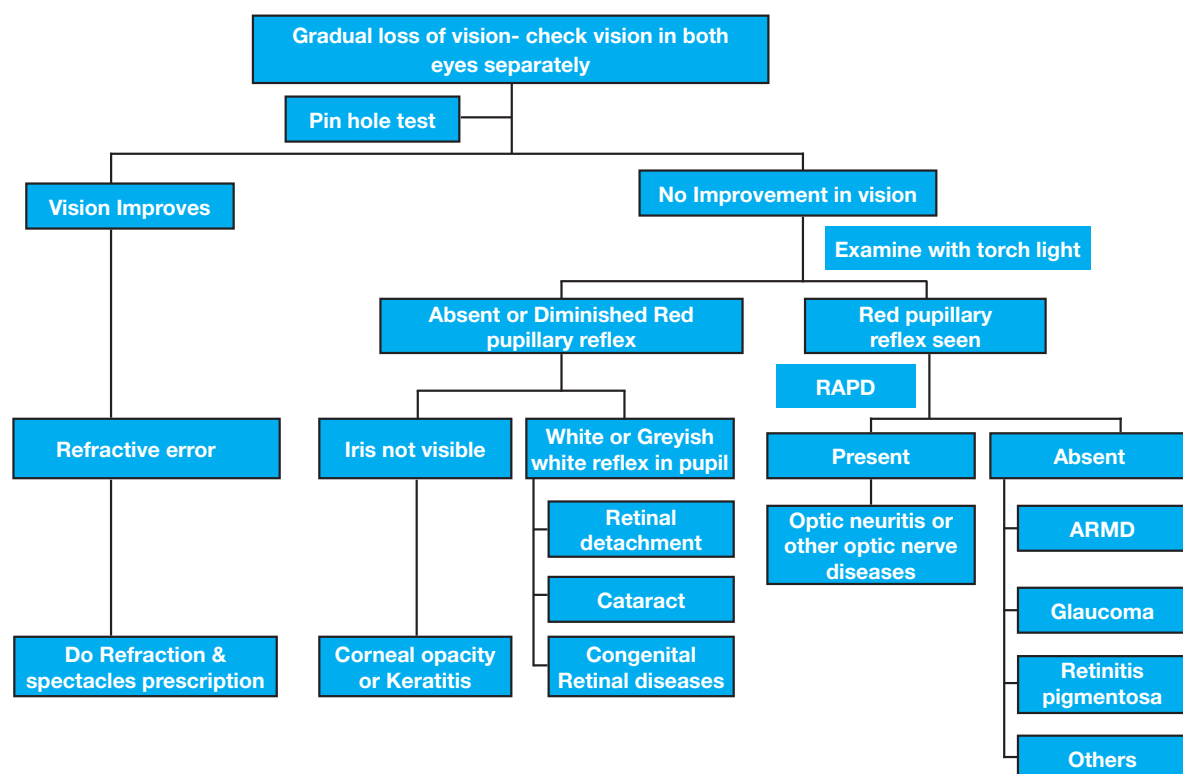
Reversible causes	Irreversible causes
Refractive error/s	Optic atrophy
Cataract	Glaucoma
Corneal blindness	Age related macular degeneration (ARMD)
Diabetic macular edema	Retinitis pigmentosa

## Approaching the patient with gradual loss of vision:

A goal-directed assessment of the patient who presents with gradual loss of vision is required. See the figure below for approach to a patient with gradual loss of vision.

**History:** Take a history of the type of visual loss, e.g., central or peripheral, and whether it is worse nearby or at distance. Central loss is found with lesions of the macula, while peripheral loss is found in glaucoma. Patients with myopia and certain retinal degeneration may experience poor vision with dim light, and those with a cataract may find bright light to affect the vision more, although this symptom depends on the morphology of the lens opacity.

**Examination:** The examination should focus on visual acuity, visual field testing, pupil testing for the presence of a relative afferent pupillary defect (RAPD), and assessment of the red reflex and funduscopy/ fundus image examination.



All cases of diminished vision, not improving with pin hole, should be referred to the nearest Eye Doctor/Eye Specialist.

**Figure 1: Approaching the patient with gradual loss of vision**

### 6.2.1 Refractive Errors:

In India, as part of the National Program for Control of Blindness and Visual Impairment, a School Eye Health Screening Program has been in place for more than two decades. Uncorrected refractive error in children can significantly affect their vision, education and psychosocial development. The overall prevalence of refractive error per 100 children up to 15 years of age in India was 8.0 (CI: 7.4-8.1) and in schools it was 10.8 (CI: 10.5-11.2)<sup>2</sup>.

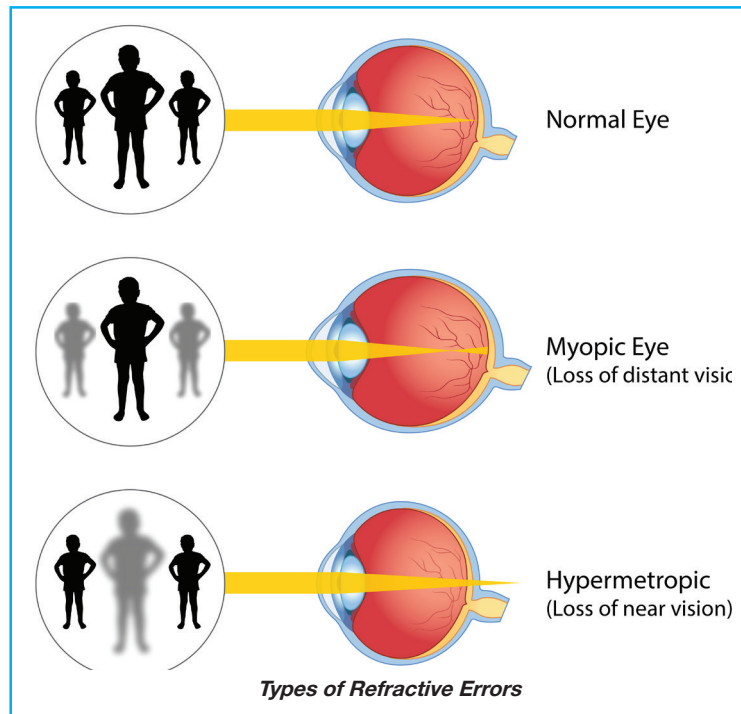
2 Saxena R, Vashist P, Tandon R, Pandey RM, Bhardawaj A, Menon V, et al. (2015) Prevalence of Myopia and Its Risk Factors in Urban School Children in Delhi: The North India Myopia Study (NIM Study). PLoS ONE 10(2): e0117349. doi:10.1371/journal.pone.0117349.



Any patient complaining of poor vision should have visual acuity measured with a 1-mm pinhole. Only parallel rays of light pass through the pinhole centrally, so that the eye does not have to refract them to obtain a clear retinal image. If the patient has a refractive error, vision will improve with the pinhole and the patient should be referred to an optometrist/ ophthalmic assistant for spectacles. If the patient already has glasses, the pinhole may be used over them, and if there is further improvement, the patient will need to change his or her spectacles.

### Types of Refractive Errors:

- **Myopia or Shortsightedness** – when a person is not able to see distant objects clearly – generally occurs in teenagers and young adults. Sometimes can affect the pre-school children also. Requires correction with concave spherical glasses.
- **Hypermetropia or Farsightedness** – patients need convex spherical glasses.
- **Astigmatism** – when light rays from different axes are not focused at one place. Patients need cylindrical glasses.
- **Presbyopia**– Usually occurs after 40 years of age and patient is unable to focus on near objects due to loss of elasticity of Lenticular suspensory ligaments.



**Equipment required:** Distance Vision box with electricity plug and/ or Snellen chart. Measuring tape to measure a distance of 6 meters (20 feet), mirror in case 20 feet space is not available so that distance is reduced to 3 meters/10 feet), a pinhole and lens set. A near vision chart or an illuminated near vision box for checking presbyopia.



*Correction of Presbyopia with use of spectacles  
Source- Dr. Rajendra Prasad Centre for  
Ophthalmic Sciences*

The patient's vision is checked in a good light, and in both eyes separately. The recording of vision is as a fraction – the numerator is 6 (6 Meters as the standard distance) and the denominator as the number denoted on the line on the Vision chart which the patient is able to read. E.g. 6/6 is normal vision. Eye Screening Tool to be used at Various Levels is given in Annexure-2.

**Treatment:** Any patient with refractory error, should be prescribed appropriate glasses for near or distance vision defect as the case may be, by referring them to a nearby Vision Centre with Ophthalmic Assistant.



Patient should be given information about proper use of glasses or contact lens. Appropriate handling of contact lens must be emphasized. Patients should be educated about the compliance on wearing glasses regularly and getting them checked at least once a year.

### 6.2.1a Squint (Cross Eyes)

Misalignment of both eyes when focusing in a primary direction of gaze. Caused by imbalance or loss of coordination between two or more extra ocular muscles.

- a) Paralytic - due to Trauma (cerebral or Ocular), Systemic diseases (Diabetes, Botulism) or conditions affecting extra ocular muscles or Cranial nerves specially 3rd, 4th or 6th nerves.
- b) Concomitant - may be intermittent or constant. Caused due to High Refractive errors (Uncorrected), any long-standing ocular condition causing obstruction to the visual axis e.g. Retinoblastoma, ROP, Macular disease, congenital Rubella, Corneal opacities and Cataract.



*Squint (Cross Eyes)*  
*Source- Dr. Rajendra Prasad Centre for Ophthalmic Sciences.*

#### **Symptoms:**

- Deviated eyes which may increase in certain gazes
- Abnormal head Posture
- Diplopia (Binocular) which may increase in some gazes
- Poor Vision
- Headache
- H/o Trauma or fever preceding the squint

#### **Management:**

- Check vision with and without glasses
- Check position of eye balls in the front gaze
- Check eye movements in all nine directions of gazes
- Any other ocular findings on torch examination may be recorded
- Counsel for need to early treatment and refer to Eye Specialist/Eye Doctor

### 6.2.1b Amblyopia (Lazy Eye)

Unilateral (rarely bilateral) decrease in the visual acuity due to disruption of the normal development of Binocular Vision during early childhood e.g. Squint, Anisometropia, etc.

When an eye condition causes a blurry or distorted image to be sent to the brain, it results in a misalignment of the images from the two eyes in the brain.

The brain learns to ignore the affected eye to overcome this confusion. Over a period of time

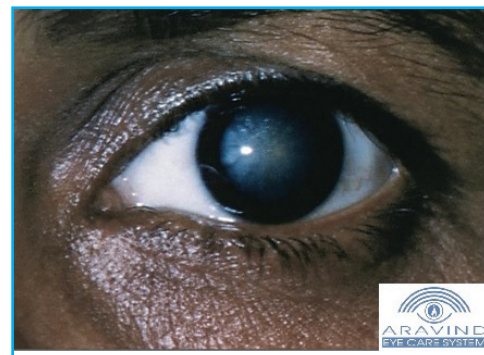
the eye is suppressed and stops functioning (Lazy Eye) and its vision cannot be restored even with the best correction of refractive error.

Early detection (before 6-8 years of age) and treatment with due compliance is a must for any improvement of the condition.

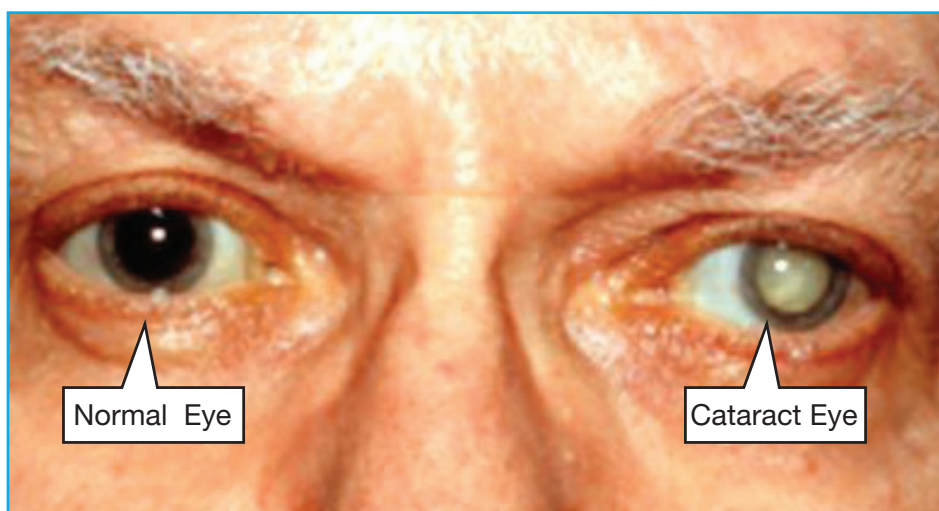
### 6.2.2 Cataract:

Cataracts are opacities of the crystalline lens and are usually bilateral. They are the leading cause of blindness worldwide.

They may be congenital (owing to intrauterine infections, such as rubella and Cytomegalovirus, or inborn errors of metabolism, such as galactosemia); traumatic; secondary to systemic disease (diabetes mellitus, myotonic dystrophy, atopic dermatitis), systemic or inhaled corticosteroid treatment, uveitis, or radiation exposure; or associated with other drugs, including statins; but age-related cataract is by far the most common type. Most persons over age 60 have some degree of lens opacity. Cigarette smoking increases the risk of cataract formation. High dietary antioxidants may delay the development of age-related cataract.



**Cataract**  
Source- Aravind Eye Hospital, Madurai



**Normal and Cataract Eye**  
Source- Dr. Rajendra Prasad Centre for Ophthalmic Sciences.

The predominant symptom is progressive blurring of vision. Glare, especially in bright light or when driving at night; development of nearsightedness may be associated with cataract. Monocular double vision may also occur in association with cataract in some cases.

**Examination:** Even in its early stages, a cataract can be seen through a dilated pupil with an ophthalmoscope or slit lamp. As the cataract matures, the retina will become increasingly difficult to visualize, until finally the fundus reflection is absent and the pupil is white (leucocoria).

**Treatment:** You, the Medical Officer at AB-HWCs, will provide medical fitness for cataract surgery to the patients. Surgical removal and replacement with an artificial lens- Intra Ocular Lens (IOL). Refer to ophthalmologist when cataract causes functional impairment. Before referral get the work up done for surgical fitness, which includes-

- Measure Blood Pressure - prescribe medicines to control blood pressure (BP). Monitor until BP is adequately controlled.
- Fasting blood sugar levels and if diabetes is suspected, check for Glycosylated haemoglobin levels (HbA1c)-
  - ▶ If diabetes is newly diagnosed or poorly controlled - prescribe medicines and counsel about dietary and lifestyle changes for adequate control of diabetes
- Exclude any respiratory tract infection - treat for same.
- If asthmatic - prescribe and monitor to control acute exacerbation.
- Screen for any eye infection - conjunctivitis before sending the patient for surgery.
- Get a Complete Blood Count done.
- Get Prothrombin time / a partial thromboplastin time done if possible.
- Do Bleeding Time and Clotting Time.
- Optimize anti-coagulation/ antiplatelet therapy if patient is taking them.

### 6.2.3 Corneal blindness: (Also Refer Chapter - 9)

Conditions which lead to opacification of the cornea will cause a reduction in visual acuity. These include trachoma in equatorial countries, which leads to entropion, trichiasis and scarring of the cornea; interstitial keratitis following infections, such as congenital syphilis, tuberculosis and measles; and climatic droplet keratopathy, which is caused by prolonged exposure to the elements, and is common in the elderly.

Corneal opacification is usually easily diagnosed by the presence of a reduction in the red reflex, with underlying iris details not being clear in the area of opacification. Generally, corneal grafting is needed to remove the opacified, scarred corneal tissue and to restore vision.

- **Gonococcal Kerato-conjunctivitis:** Gonococcal conjunctivitis is usually acquired through contact with infected genital secretions, typically causes copious purulent discharge. It is an ophthalmologic emergency because corneal involvement may rapidly lead to perforation. A single 1 g dose of intramuscular ceftriaxone is usually adequate. Topical antibiotics such as erythromycin may be added. Other sexually transmitted diseases, including chlamydiosis, syphilis, and Human immunodeficiency virus (HIV) infection, should be considered and excluded. Routine treatment for chlamydia infection is recommended. However, if gonococcal conjunctivitis is suspected patient should be urgently referred to ophthalmologist.

## 6.2.4 Glaucoma: A Sneak Thief of Vision (Also Refer Chapter - 10)

Glaucoma is a type of “**optic neuropathy**” with cupping of the optic disc, a characteristic pattern of visual field loss, and in most cases, raised IOP. Measured by tonometry, normal IOP is 10-21 mmHg. Visual acuity and IOP may be normal in a patient with glaucoma. Glaucoma is classified as acute or chronic, depending on the rate of onset, and primary or secondary, depending on whether or not there is an underlying ocular cause. This can further be divided into open or closed angle, depending on the gonioscopic findings during assessment of the anterior chamber angle.

The most common type is chronic primary open-angle glaucoma. It is an asymptomatic disease with insidious onset, and is a result of trabecular resistance to aqueous outflow. Patients with raised IOP, but no optic neuropathy or field loss, are referred to as ocular hypertensives. Underlying ocular causes of secondary glaucomas may be cataracts, trauma, inflammation or neoplasia. Risk factors for primary open-angle glaucoma include genetic, having myopia, being over 40 years of age, and having diabetes and uncontrolled hypertension. Symptoms vary, but generally there is vague pain around eyes and headache with frequent change of glasses. Visual acuity may be normal early on (asymptomatic) as central vision is preserved until late in the disease, or the patient may be blind on presentation.

Glaucoma is diagnosed by looking at the disc through ophthalmoscopy or by looking at the fundal image, as well as assessing the visual fields and measuring IOP. The optic cup is a pale depression in the centre of the disc. The disc is made up of neural tissue. A cup-to-disc ratio of  $> 0.5$  is suggestive of glaucomatous cupping, in which the loss of nerve fibres leads to pathological enlargement of the cup. Other signs of glaucomatous cupping that may be seen include baring, bayoneting and nasalisation of the disc vessels; disc haemorrhages; exposed lamina cribrosa (laminar dot sign); notching of the cup and disc pallor. Loss of visual field in glaucoma follows the pattern of the retinal nerve fibre layer, and these defects are detected by perimetry. Tunnel vision is found in advanced cases and eventually ends in blindness.

**Management** includes referral to an ophthalmologist for treatment and regular follow-up. Patients are monitored for progression of cupping and field loss, which can be prevented by lowering the IOP. This can be achieved medically with topical agents (drops), e.g.,  $\beta$  (beta blockers) and prostaglandin analogues, or surgically with drainage procedures, e.g., trabeculectomy. Patients with a family history of glaucoma in a first-degree relative should be prioritized for screening.

**For painless Gradual dimness of vision - Cataract, Open Angle Glaucoma, Refractive Errors must be looked for and managed accordingly.**

**For painful Gradual loss of Vision - Either corneal infections/ Ulcers or Uveitis are responsible and Local antibiotics and/or Nonsteroidal anti-inflammatory drugs (NSAIDs) may be started and patient referred to a higher centre (District Hospital).**

**Any patient above 40 Years of age, or having family history of glaucoma or suffering from Diabetes Mellitus (DM) or Hypertension (HTN) should be referred to an Eye Doctor/ Eye Specialist for Screening of Glaucoma.**



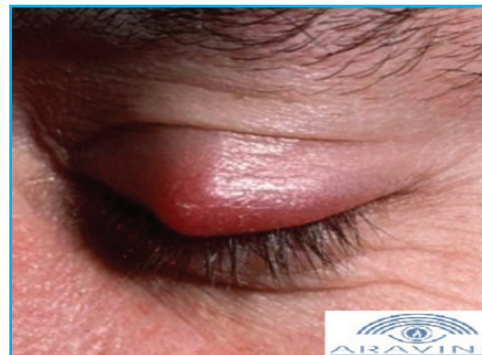
## CHAPTER - 7

# COMMON EYE CONDITIONS - EYELIDS AND LACRIMAL SYSTEM

### 7.1 Hordeolum:

Hordeolum externum (stye) is a common staphylococcal infection of eyelash follicle that is characterized by a localized red, swollen, acutely tender area on the upper or lower lid with a pus point at the base of the eyelash. Internal hordeolum is a meibomian gland abscess that usually points onto the conjunctival surface of the lid; external hordeolum or stye usually is smaller and on the margin.

**Treatment:** Dry warm compresses are helpful. Epilation of Eyelash may be indicated if pus point present or resolution does not begin within 48 hours. An antibiotic ointment (erythromycin) applied to the eyelid every 3 hours may be beneficial during the acute stage.

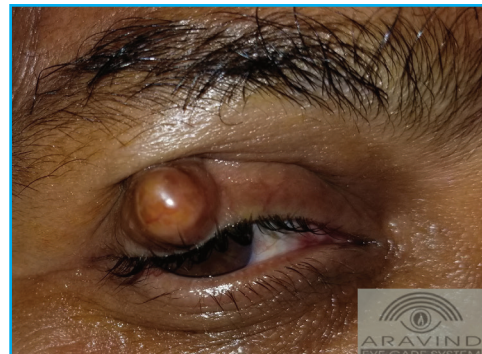

**Hordeolum**  
Source- Aravind Eye Hospital, Madurai

### 7.2 Chalazion:

It is a granulomatous inflammation of a meibomian gland that may follow an internal hordeolum. It appears as a hard, nontender swelling on the upper or lower lid with redness and swelling of the adjacent conjunctiva. If the chalazion is large and presses the cornea, vision may be distorted.

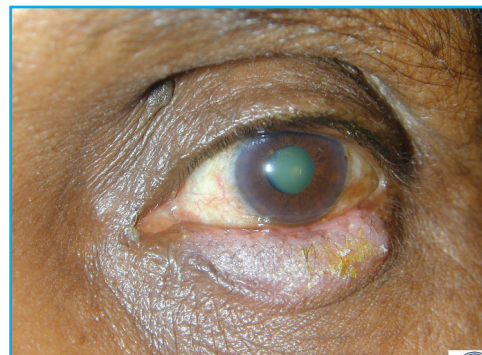
**Treatment** is usually by incision and curettage but corticosteroid injection may also be effective. Refer to ophthalmologist for treatment.



**Chalazion**  
Source- Aravind Eye Hospital, Madurai

### 7.3 Blepharitis

Blepharitis is a chronic bilateral inflammatory condition of the lid margins. Anterior blepharitis involves the eyelid skin, eyelashes, and associated glands. It may be ulcerative, or seborrheic in association with seborrhea (scales) of the scalp, brows, and ears. Posterior blepharitis results from inflammation of the meibomian glands. There may be bacterial infection associated with it.



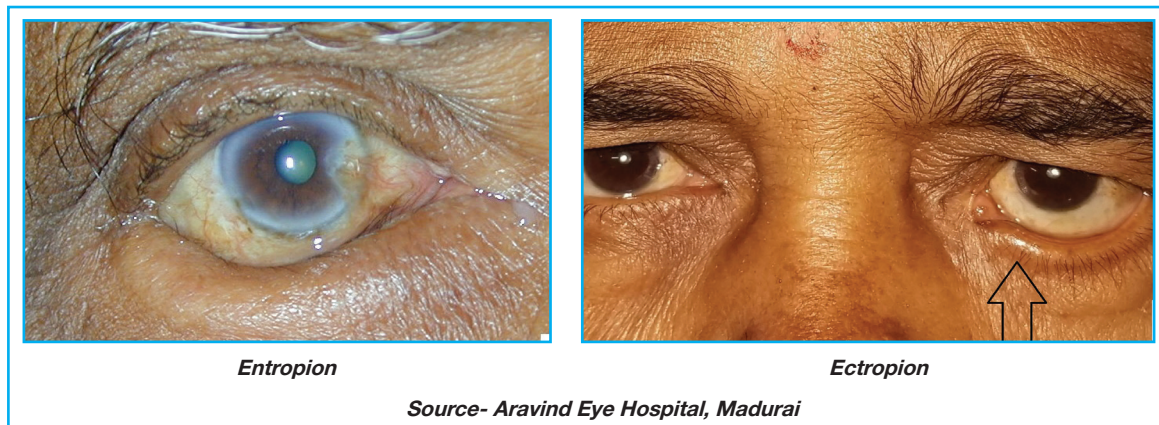
**Blepharitis**  
Source- Aravind Eye Hospital, Madurai

**Symptoms** are irritation, burning, and itching. In anterior blepharitis, the eyes are “red-rimmed” and scales or granulations can be seen clinging to the eye-lashes. In posterior blepharitis, the lid margins are red and the meibomian glands and their orifices are inflamed. The tears may be frothy or abnormally greasy. Blepharitis is a common cause of recurrent conjunctivitis. Both anterior and, more particularly, posterior blepharitis may be complicated by abnormal lid or lash positions, producing trichiasis (eye lash irritating cornea); epithelial keratitis of the lower third of the cornea; marginal corneal infiltrates; and inferior corneal vascularization and thinning.

**Treatment:** Anterior blepharitis is usually controlled by cleanliness of the lid margins, eyebrows, and scalp. Scales should be removed from the lids daily with a hot wash cloth or a damp cotton applicator and baby shampoo. In acute exacerbations, an anti-staphylococcal antibiotic eye ointment, is applied daily to the lid margins. In mild posterior blepharitis, regular meibomian gland expression may be sufficient to control symptoms.

Inflammation of the conjunctiva and cornea indicates a need for more active treatment, including long-term low-dose oral antibiotic therapy, like with doxycycline (100 mg daily) or erythromycin (250 mg three times daily), and short-term topical corticosteroids. Topical therapy with antibiotics like ciprofloxacin 0.3% ophthalmic solution twice daily, may be helpful but should be restricted to short courses. Ophthalmologist referral if initial treatment does not improve the symptoms.

## 7.4 Entropion and Ectropion:



**Entropion:** Inward turning of usually the lower lid occurs occasionally in older people as a result of degeneration of the lid fascia, or may follow extensive scarring of the conjunctiva and eyelid due to any cause. This can cause constant irritation of cornea by the inturned lashes leading to corneal ulceration and then corneal opacity. Surgical correction of eyelid is required if the eyelashes rub on the cornea. For surgical correction patient should be referred to ophthalmologist.

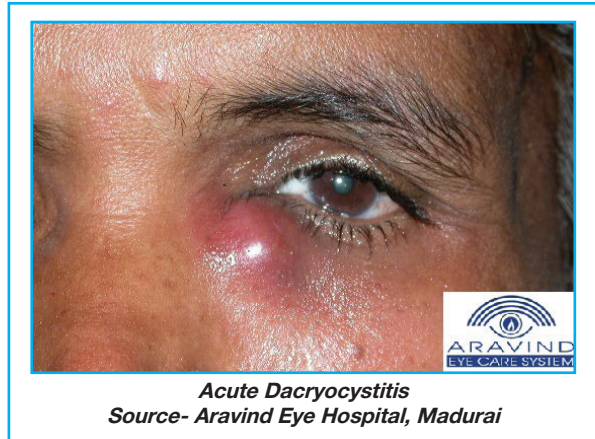**Ectropion** (outward turning of the lower lid) is common with advanced age. Surgery is required if there is excessive tearing, exposure keratitis (corneal inflammation due to exposure), or a cosmetic problem.

## 7.5 Growth/ Tumour of eyelid:

Eyelid tumours are usually benign. However, any growth should be assessed by an ophthalmologist. Surgery for any lesion involving the lid margin should be performed by an ophthalmologist to avoid deformity of the lid. Otherwise, very-small lesions can also be excised by the non-ophthalmologist.

## 7.6 Dacryocystitis:

Dacryocystitis is infection of the lacrimal sac usually due to congenital or acquired obstruction of the nasolacrimal system. It may be acute or chronic and occurs most often in infants and in persons over 40 years. It is usually unilateral. The usual infectious organisms are *Staphylococcus aureus* and *Streptococci* in acute dacryocystitis and *Staphylococcus epidermidis*, *streptococci*, or gram-negative bacilli in chronic dacryocystitis. Acute dacryocystitis is characterized by pain, swelling, tenderness, and redness in the tear sac area; purulent material may be expressed if the sac is pressed gently upwards. In chronic dacryocystitis, tearing and discharge are the principal signs, and mucus or pus may also be expressed.



**Treatment:** For acute dacryocystitis systemic antibiotic therapy should be initiated and patient referred to ophthalmologist as relief of the obstruction surgically is the only cure. Congenital nasolacrimal duct obstruction is also common and can often resolve spontaneously. However, the child should be referred to ophthalmologist for assessment and planning management.

## CHAPTER-8

# COMMON EYE CONDITIONS - CONJUNCTIVAL CONDITIONS

### 8.1 Conjunctivitis:

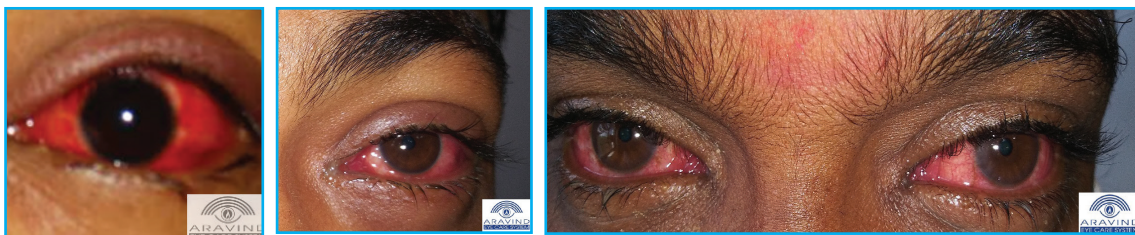
Conjunctivitis is a disease characterized by inflammation of the conjunctiva. It may be acute or chronic. Most cases are due to viral or bacterial (including gonococcal and chlamydial) infection. Other causes include keratoconjunctivitis sicca, allergy, chemical irritants, and deliberate self-harm. The mode of transmission of infectious conjunctivitis is usually direct contact via fingers, towels, handkerchiefs, etc. to the fellow eye or to other persons. Conjunctivitis should be differentiated from acute uveitis, acute glaucoma, and corneal disorders.

	Acute conjunctivitis	Acute anterior Uveitis (Iritis)	Acute angle closure glaucoma	Corneal trauma or infection
<b>Incidence</b>	Extremely common	Common	Uncommon	Common
<b>Discharge</b>	Moderate to copious	None	None	Watery or purulent
<b>Vision</b>	No effect	Often blurred	Marked blurred	Usually blurred
<b>Pain</b>	Mild	Moderate	Severe	Moderate-Severe
<b>Conjunctival injection</b>	Diffuse; more toward fornices	Mainly circumcorneal	Mainly circumcorneal	Mainly circumcorneal
<b>Cornea</b>	Clear	Usually clear	Cloudy	Clarity change related to cause
<b>Pupil size</b>	Normal	Small	Moderately dilated	Normal or small
<b>Pupillary light response</b>	Normal	Poor	None	Normal
<b>Intraocular pressure</b>	Normal	Usually normal but may be low or elevated	Markedly elevated	Normal

### 8.2 Viral Conjunctivitis:

There is usually bilateral disease with copious watery discharge, often associated with marked foreign body sensation, and a follicular conjunctivitis. Infection spreads easily. Eye clinics and contaminated swimming pools are sometimes the source of infection. Epidemic keratoconjunctivitis, may result in visual loss due to corneal subepithelial infiltrates. The disease lasts at least 2 weeks. Infection with certain adenovirus types may be associated with pharyngitis, fever, malaise, and preauricular lymph node enlargement (pharyngoconjunctival fever). The disease usually lasts for about 10 days. Viral conjunctivitis may also be due to Herpes Simplex Virus (HSV), when it is usually unilateral and may be associated with lid vesicles. Enterovirus or coxsackievirus conjunctivitis can characteristically cause acute hemorrhagic conjunctivitis.



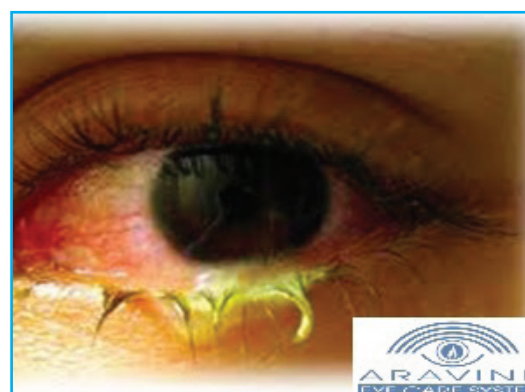

**Viral Conjunctivitis**  
Source- Aravind Eye Hospital, Madurai

**Treatment:** Except for Herpes Zoster infection for which treatment with topical (e.g, Acyclovir) antivirals is recommended, there is no specific treatment. Cold compresses reduce discomfort and topical antibiotics can be prescribed to prevent secondary bacterial infection.

### 8.3 Bacterial Conjunctivitis:

In bacterial conjunctivitis, there is usually a copious purulent discharge. There is no blurring of vision and only mild discomfort. In severe cases gonococcal infection should be suspected. The disease is usually self-limited, lasting about 10-14 days.



**Bacterial Conjunctivitis**  
Source- Aravind Eye Hospital, Madurai

### 8.4 Gonococcal Conjunctivitis:

Gonococcal conjunctivitis is usually acquired through contact with infected genital secretions, typically causes copious purulent discharge. It is an ophthalmologic emergency because corneal involvement may rapidly lead to perforation.

**Treatment:** Other sexually transmitted diseases, including chlamydiosis, syphilis, and HIV infection, should be considered and excluded. A single 1 g dose of intramuscular ceftriaxone is usually adequate. Topical antibiotics such as erythromycin may be added. Routine treatment for chlamydia infection is recommended. However, for gonococcal conjunctivitis or if it is suspected patient should be urgently referred to ophthalmologist.

### 8.5 Chlamydia Keratoconjunctivitis:

- **Trachoma:** Trachoma is one of the common infectious cause of blindness worldwide. Recurrent episodes of infection in childhood manifest as bilateral follicular conjunctivitis, epithelial keratitis, and corneal vascularization (pannus). Scarring (cicatrization) of the tarsal (eye lid) conjunctiva leads to entropion and trichiasis in adulthood, with secondary central corneal scarring. Treatment should be started on the basis of clinical findings. A single 1 g dose of oral Azithromycin is the preferred drug. Improvements in hygiene and living conditions probably have contributed more to the marked reduction in the prevalence of trachoma during the past 25 years and should be emphasized. Local Azithromycin ointment may be given. Surgical treatment includes correction of eyelid

deformities and corneal transplantation. Patient with scarring and entropion should be referred to ophthalmologist.

- **Inclusion conjunctivitis:** Inclusion conjunctivitis is usually associated with genital infection, the eye being involved following contact with genital secretions. The disease starts with acute redness, discharge, and irritation. The eye findings consist of follicular conjunctivitis with mild keratitis. A nontender preauricular lymph node can often be palpated. Healing usually leaves no sequelae. Diagnosis can be rapidly confirmed by immunologic tests or polymerase chain reaction on conjunctival samples. Treatment is with a single dose of azithromycin, 1 g orally. Before treatment, all cases should be assessed for genital tract infection and other sexually transmitted diseases. Patient should be referred for ophthalmologist assessment.

## 8.6 Dry Eyes (Keratoconjunctivitis Sicca):

This is a common disorder, more commonly affecting older women. Hypofunction of the lacrimal glands, causing loss of the aqueous component of tears, may be due to aging, hereditary disorders, systemic disease (e.g., Sjogren syndrome), or systemic drugs. Excessive evaporation of tears may be due to environmental factors (e.g., a hot, dry, or windy climate) or abnormalities of the lipid component of the tear film, as in blepharitis. Mucin deficiency may be due to vitamin A deficiency, or conjunctival scarring from trachoma, Stevens-Johnson syndrome and related conditions, mucous membrane pemphigoid, burns, or topical drugs or their preservatives.

Vitamin A deficiency can cause dryness of conjunctiva and cornea in young children. This may also cause night blindness and bitot's spots. If not treated early, this may lead to keratomalacia, corneal scarring and corneal opacity. The condition is also precipitated, if the child is malnourished and suffers a bout of severe Diarrhoea or Measles infection. Regular supplementation by prophylactic dose of vitamin A syrup (200,000 IU) every six months till the child is five years old can prevent this deficiency. A Vitamin A rich diet also has a beneficial effect.

Regular consumption of vitamin A rich foods such as milk and milk products, butter, ghee; whole egg, liver, meat, chicken, fish; dark green leafy vegetables like Amaranthus leaves (chulai), drumstick leaves, methi (fenugreek) leaves, spinach (palak), mustard leaves (sarson saag), turnip leaves, coriander, radish leaves, bathua leaves, mint leaves; yellow and orange vegetables and fruits like carrots, tomato, sweet potato (shakarkandi), papaya, mango, apricots (khoomani), dates, etc. and appropriate breastfeeding (colostrum is rich in Vitamin A). Home garden/Community Garden to grow vitamin rich vegetables and fruits should be encouraged, wherever applicable.



*Vitamin A rich foods*

The patient complains of dryness, redness, or foreign body sensation. In severe cases, there is persistent marked discomfort, with photophobia, difficulty in moving the eyelids, and often excessive mucus secretion. In many cases, inspection reveals no abnormality, but on slit-lamp examination there are subtle abnormalities of tear film stability. In very severe cases, there is marked conjunctival redness, loss of the normal conjunctival and corneal luster, epithelial keratitis that may progress to frank ulceration, and mucous strands. The Schirmer test, which measures the rate of production of the aqueous component of tears, may be helpful.

**Treatment:** Aqueous deficiency can be treated with various types of artificial tears. Such as drop preparations containing a mucomimetic such as methylcellulose. Artificial tear preparations are generally very safe and without side effects. However, preservatives included in some preparations to maintain sterility are potentially toxic and allergenic and may cause keratitis and cicatrizing conjunctivitis in frequent users. The development of such reactions may be misinterpreted as a worsening of the dry eye state requiring more frequent use of the artificial tears and leading in turn to further deterioration, rather than being recognized as a need to change to a preservative-free preparation.

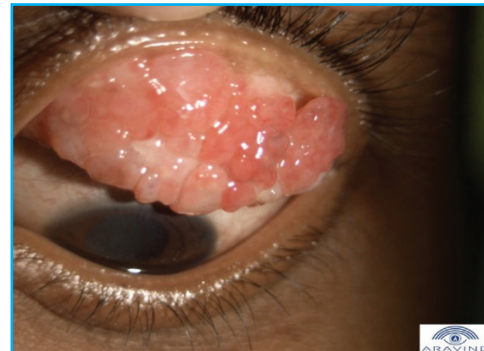**When to refer:** If patient has severe symptoms are diagnosis is uncertain patient should be referred to ophthalmologist for assessment and further management.

## 8.7 Allergic Eye Disease:

Allergic eye disease is common and takes a number of different forms but all are expressions of atopy. It may be associated with atopic asthma, atopic dermatitis, or allergic rhinitis.

**Clinical Findings:** Symptoms include itching, tearing, redness, stringy discharge, and occasionally, photophobia and visual loss. Allergic conjunctivitis is a benign disease, occurring usually in late childhood and early adulthood. It may be seasonal (hay fever), developing usually during the spring or summer, or perennial. Clinical signs are limited to conjunctival hyperemia (redness) and edema (chemosis), the latter at times being marked and sudden in onset. **Vernal keratoconjunctivitis** tends to occur in late childhood and early adulthood.

It is usually seasonal, with a predilection for the spring. Large “cobblestone” papillae are noted on the upper tarsal conjunctiva. There may be lymphoid follicles at the limbus. Atopic keratoconjunctivitis is a more chronic disorder of adulthood. Both the upper and the lower tarsal conjunctivas exhibit a fine papillary conjunctivitis with fibrosis, resulting in forniceal shortening and entropion (inversion of eyelid) with trichiasis (eyelash rubbing against the eyeball). Corneal involvement, including refractory ulceration, may frequently occur during exacerbations of both vernal and atopic keratoconjunctivitis.



*Vernal Keratoconjunctivitis*  
Source- Aravind Eye Hospital, Madurai

### Treatment

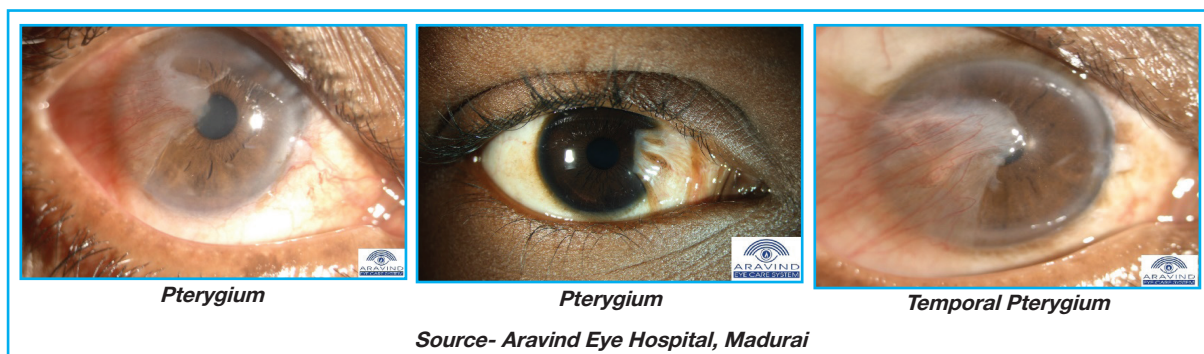
- Mild and Moderately Severe Allergic Eye Disease: Topical treatments antihistamine drops and mast cell stabilizers, and nonsteroidal anti-inflammatory drugs are generally prescribed. Topical vasoconstrictors, alone or in combination with antihistamines such



as antazoline and pheniramine, are of limited efficacy in allergic eye disease and may produce rebound hyperemia and follicular conjunctivitis. Systemic antihistamines may be useful in prolonged atopic keratoconjunctivitis.

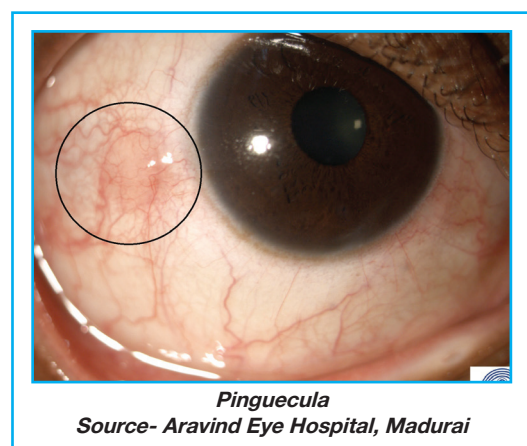
- In allergic conjunctivitis, if certain specific allergens are identified, they should be avoided if possible. In vernal keratoconjunctivitis, a cooler climate may provide significant symptomatic benefit.
- Acute Exacerbations and Severe Allergic Eye Disease: Topical corticosteroids are essential to control acute exacerbations of both vernal and atopic keratoconjunctivitis. Corticosteroid-induced side effects, including cataracts, glaucoma, and exacerbation of herpes simplex keratitis, are major problems. Therefore, patient should be referred to ophthalmologist for assessment and initiation of treatment.

## 8.8 Pinguecula and Pterygium



Pinguecula is a yellow, elevated conjunctival nodule, more commonly on the nasal side, in the area of the palpebral fissure. It is common in persons over age 35 years.

Pterygium is a fleshy, triangular encroachment of the conjunctiva onto the nasal side of the cornea and is usually associated with prolonged exposure to wind, sun, sand, and dust. Pinguecula and pterygium are often bilateral. Pingueculae rarely grow but may become inflamed (pingueculitis). Pterygia become inflamed and may grow.

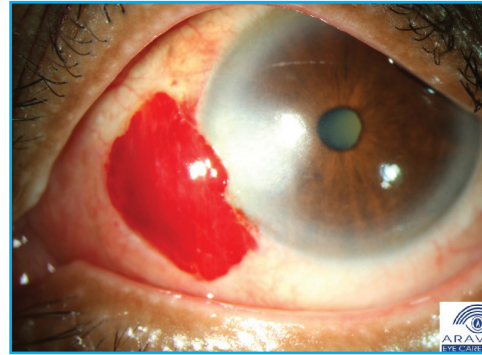


**Treatment:** No treatment is usually required for inflammation of pinguecula or pterygium, but artificial tears are often beneficial, and short courses of topical nonsteroidal anti-inflammatory agents or weak corticosteroids four times a day may be initiated in consultation with ophthalmologist. The indications for excision of pterygium are growth that threatens vision by encroaching on the visual axis, marked induced astigmatism, or severe ocular irritation. Recurrence is common and often more aggressive than the primary lesion.

## 8.9 Subconjunctival Hemorrhage

Subconjunctival hemorrhage is diagnosed clinically. It is **usually painless and harmless** with blood reabsorption taking place over a few weeks, and no specific treatment is needed. Check blood pressure to rule out hypertension. Warm compresses and ophthalmic lubricants (e.g, methylcellulose, artificial tears) may help in relieving symptoms.

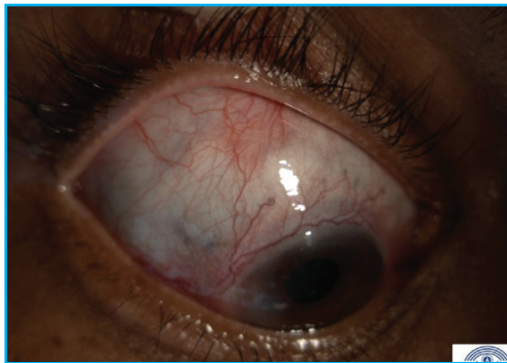
If pain is present, a cause must be identified. Checking for corneal involvement or penetrating injury is must and to make an immediate referral to ophthalmologist if so found. Recurrent hemorrhages may require workup for bleeding disorders. If the patient is taking warfarin or any other anti-coagulants, the International Normalized Ratio (INR) should be checked or referral be made for specialist assessment.



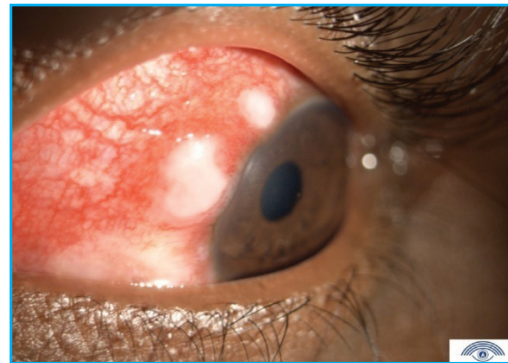
*Subconjunctival Hemorrhage*  
*Source- Aravind Eye Hospital, Madurai*

## 8.10 Episcleritis/ Scleritis

Episcleritis is a localized area of inflammation involving superficial layers of episclera. It is usually self-limiting (lasting up to three weeks) and is diagnosed clinically. Investigation of underlying causes is needed only for recurrent episodes and for symptoms suggestive of associated systemic diseases, such as rheumatoid arthritis.



*Episcleritis*



*Scleritis*

*Source- Aravind Eye Hospital, Madurai*

**Treatment** involves supportive care and use of artificial tears/ lubricants. Topical steroids may be useful for severe cases which should be prescribed in consultation with Ophthalmologist. Ophthalmology referral is required for severe disease, recurrent episodes, an unclear diagnosis (early scleritis), and if there is worsening of symptoms on treatment.

## CHAPTER - 9

# COMMON EYE CONDITIONS - CORNEAL CONDITIONS, UVEITIS

### 9.1 Corneal Abrasions:

A patient with a corneal abrasion complains of severe pain and photophobia. There is often a history of trauma to the eye, commonly involving a fingernail, piece of paper, or contact lens. Visual acuity is recorded, and the cornea and conjunctiva are examined with a light and loupe to rule out a foreign body.

If needed, short-term topical anesthetics (topical Proparacaine 0.5%) may be used to facilitate the eye examination. In patients with corneal abrasion, it should be checked if there is a retained foreign body under the upper eyelid. Corneal abrasions which are larger, not responding to treatment and which are suspected to be due to HSV will require ophthalmologist referral.

**Treatment** includes supportive care, cycloplegics (atropine 1%, homatropine 2%, and tropicamide 1%), and pain control (topical nonsteroidal anti-inflammatory drugs [NSAIDs] or oral analgesics). The need of topical antibiotics for uncomplicated abrasions is unproven. The eye patches also do not improve patient comfort or healing of corneal abrasion. **All steroid preparations are contraindicated** in patients with corneal abrasion.

**Referral** to an ophthalmologist is warranted except for most minor abrasions and also if symptoms worsen or do not resolve within 2 days of initiating treatment.

Treatment includes antibiotic ophthalmic ointment, mydriatic and analgesics either topical or oral nonsteroidal anti-inflammatory agents. Padding the eye is not required for small abrasions.

### 9.2 Corneal Ulcer:

Corneal ulcers are most commonly due to infection by bacteria, viruses, fungi, or amoebae. Noninfectious causes may be complicated by infection and ulcer include neurotrophic keratitis (resulting from loss of corneal sensation), exposure keratitis (due to inadequate eyelid closure), severe dry eye, severe allergic eye disease, and various inflammatory disorders that may be purely ocular or part of a systemic vasculitis.

Patients complain of pain, photophobia, tearing, and reduced vision. The eye is red, with predominantly circumcorneal injection, and there may be purulent or watery discharge. The corneal appearance varies according to the underlying cause.

Delayed or ineffective treatment of corneal ulceration may lead to devastating consequences with corneal scarring or intraocular infection. Prompt referral is essential.

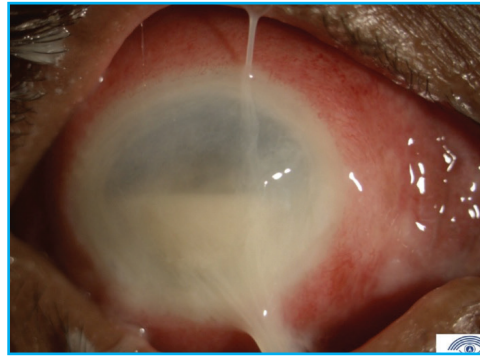
**Any patient with an acute painful red eye and corneal abnormality should be referred emergently to an ophthalmologist.**

## 1. Infectious Keratitis:

### i. Bacterial Keratitis:

Bacterial keratitis usually pursues an aggressive course. Precipitating factors include wearing contact lens, especially overnight and corneal trauma, including refractive surgery.

On examination the cornea is hazy, with an ulcer and adjacent stromal abscess. Hypopyon (pus in anterior chamber of eye) is often present and can be seen.



**Bacterial Keratitis**  
Source- Aravind Eye Hospital, Madurai

Treatment with fortified topical antibiotic drops applied hourly day and night for at least the first 48 hours. Fluoroquinolones, such as ofloxacin 0.3% or ciprofloxacin 0.3%, are commonly used as first-line agents. Although early adjunctive topical corticosteroid therapy may improve visual outcome, it should be prescribed only by an ophthalmologist.

**Any patient with suspected bacterial keratitis must be referred emergently to an ophthalmologist.**

### ii. Herpes Simplex Keratitis:

The ability of the virus to colonize the trigeminal ganglion leads to recurrences that may be precipitated by fever, excessive exposure to sunlight, or immunodeficiency.

Primary infection may manifest as eyelid, conjunctival, and corneal ulceration. The dendritic (branching) corneal ulcer is the most characteristic manifestation of recurrent ocular disease. More extensive (“geographic”) ulcers also occur, particularly if topical corticosteroids have been used. The corneal ulcers are most easily seen after instillation of fluorescein and examination with a blue light. Such corneal epithelial disease in itself does not lead to corneal scarring.

It responds well to simple debridement and patching. More rapid healing can be achieved by the addition of topical antivirals, drops, gel, or ointment, or oral antivirals, such as Acyclovir, 400 mg five times daily. Long-term oral Acyclovir, 400 mg twice daily, or Valacyclovir, 500 mg once daily, reduces the rate of recurrent epithelial disease, particularly in atopic individuals.

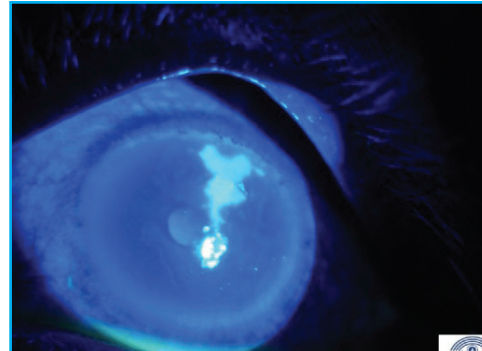
Stromal herpes simplex keratitis produces increasingly severe corneal opacity with each recurrence. Topical antivirals alone are insufficient to control stromal disease, so topical corticosteroids are used as well but they may enhance viral replication, exacerbating epithelial disease, and steroid dependence is common. Oral acyclovir, 200-400 mg five times a day, is often helpful in the treatment of severe herpetic keratitis. Severe stromal scarring may require corneal grafting, but the overall outcome is relatively poor. **Caution:** For patients with known or possible herpetic disease, topical corticosteroids should be prescribed only with ophthalmologic supervision.



**Any patient with a history of herpes simplex keratitis and an acute red eye should be referred urgently to an ophthalmologist.**

### **iii. Herpes Zoster Ophthalmicus:**

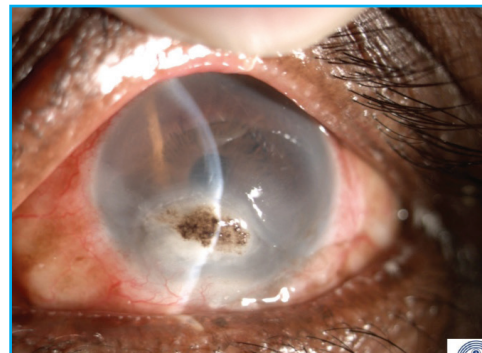
Herpes zoster frequently involves the ophthalmic division of the trigeminal nerve. It presents with malaise, fever, headache, and periorbital burning and itching. These symptoms may precede the eruption by a day or more. The rash is initially vesicular, quickly becoming pustular and then crusting. Involvement of the tip of the nose predicts involvement of the eye. Ocular signs include conjunctivitis, keratitis, episcleritis, and anterior uveitis, often with elevated intraocular pressure. Recurrent anterior segment inflammation, neurotrophic keratitis, and posterior subcapsular cataract can occur as its long-term complications. Optic neuropathy, cranial nerve palsies, acute retinal necrosis, and cerebral angiitis may occur occasionally. HIV infection is an important risk factor for herpes zoster ophthalmicus and increases the likelihood of complications. High-dose oral Acyclovir (800 mg five times a day), started within 72 hours after the appearance of the rash reduces the incidence of ocular complications. Any patient with suspected herpes zoster ophthalmicus and ocular symptoms or signs should be referred urgently to an ophthalmologist.



**Herpes Zoster Ophthalmicus**  
Source- Aravind Eye Hospital, Madurai

### **iv. Fungal Keratitis:**

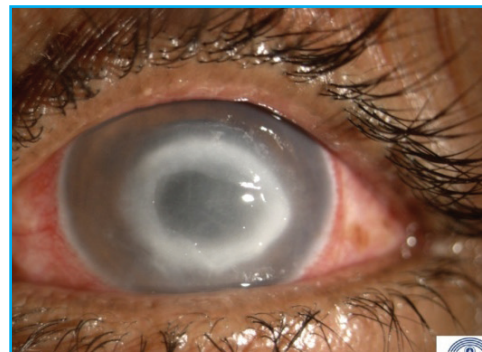
Fungal keratitis tends to occur after corneal injury involving plant material or in an agricultural setting, in eyes with chronic ocular surface disease, and also increasingly in contact lens wearers. It is usually an indolent process, with the cornea characteristically having multiple stromal abscesses and relatively little epithelial loss. Intraocular infection is common. Whenever the history or corneal appearance is suggestive of fungal disease the patient should be referred to ophthalmologist. Diagnosis is often delayed and treatment is difficult.



**Fungal Keratitis**  
Source- Aravind Eye Hospital, Madurai

### **v. Acanthamoeba Keratitis:**

Acanthamoeba infection is an important cause of keratitis in contact lens wearers. Although severe pain with perineural and ring infiltrates in the corneal stroma is characteristic, it is not specific and earlier forms with changes confined to the corneal epithelium are identifiable. Delayed diagnosis and prior treatment with topical steroids adversely affect the visual outcome.



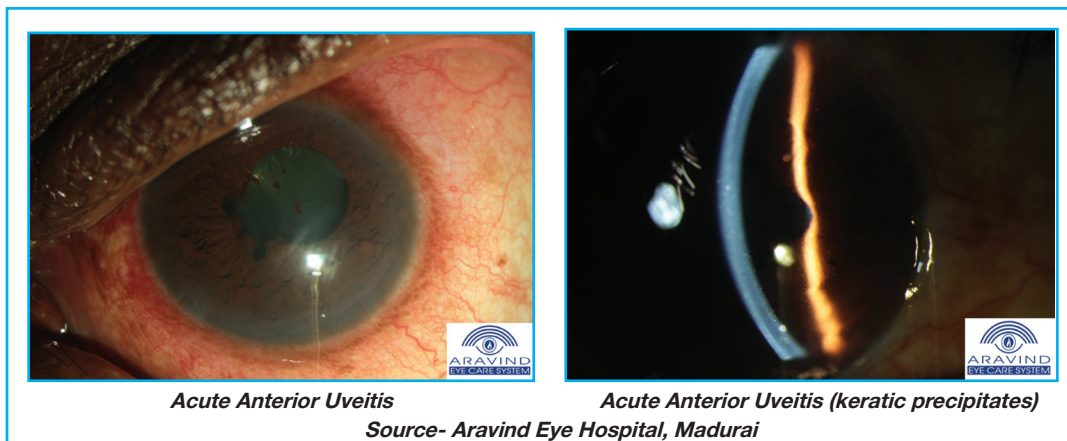
**Acanthamoeba Keratitis**  
Source- Aravind Eye Hospital, Madurai

Corneal grafting may be required after resolution of infection to restore vision. If acanthamoeba keratitis is suspected patient should be urgently referred to ophthalmologist.

### 9.3 Uveitis:

Uveitis is usually immunologic but can also occur due to infective or neoplastic pathology. Intraocular inflammation (uveitis) is classified according to the clinical signs (acute or chronic, non-granulomatous or granulomatous uveitis) or by its distribution - involving the anterior, intermediate, or posterior segments of the eye or panuveitis (in which all segments are affected). The common types are acute non-granulomatous anterior uveitis, granulomatous anterior uveitis, and posterior uveitis. Acute non-granulomatous anterior uveitis may be associated with ankylosing spondylitis, reactive arthritis, psoriasis, ulcerative colitis, and Crohn disease.


**Anterior uveitis** is characterized by inflammatory cells and flare within the aqueous. In severe cases there may be hypopyon (layered collection of white cells) and fibrin within the anterior chamber. Cells may also be seen on the corneal endothelium as keratic precipitates (KPs). In granulomatous uveitis there are large “mutton-fat” KPs, and iris nodules may be seen. In non-granulomatous uveitis the KPs are smaller and iris nodules are not seen. The pupil is usually small, and with the development of posterior synechiae (adhesions between the iris and anterior lens capsule) it also becomes irregular.



**Clinical presentation:** Non-granulomatous anterior uveitis tends to present acutely with unilateral pain, redness, photophobia, and visual loss. Granulomatous anterior uveitis is usually indolent, causing blurred vision in a mildly inflamed eye.

**Posterior uveitis:** In posterior uveitis there are cells in the vitreous. Inflammatory lesions may be present in the retina or choroid. Fresh lesions are yellow with indistinct margins and there may be retinal hemorrhages, whereas older lesions have more definite margins and are commonly pigmented. Retinal vessel sheathing may occur adjacent to such lesions or more diffusely. In severe cases, vitreous opacity precludes visualization of retinal details.

**Clinical presentation:** Posterior uveitis presents with gradual visual loss in a relatively quiet eye. Bilateral involvement is common. Visual loss may be due to vitreous haze and opacities, inflammatory lesions involving the macula, macular edema, retinal vein occlusion, or rarely associated optic neuropathy.



**Treatment:** Anterior uveitis usually responds to topical corticosteroids. Occasionally periocular corticosteroid injections or even systemic corticosteroids are required. Dilation of the pupil is important to relieve discomfort and prevent posterior synechiae. Posterior uveitis more commonly requires systemic, periocular or intravitreal corticosteroid therapy and occasionally systemic immunosuppression with agents such as azathioprine, tacrolimus, cyclosporine, mycophenolate, or methotrexate, of which the last also can be administered by intraocular injection. The use of biologic therapies is increasing. Pupillary dilation is not usually necessary. If an infectious cause is identified, specific antimicrobial therapy may be indicated. In general, the prognosis for anterior uveitis, particularly the non-granulomatous type, is better than for posterior uveitis.

**When to Refer:** Any patient with suspected acute uveitis should be referred urgently to an ophthalmologist or emergently if visual loss or pain is severe. Any patient with suspected chronic uveitis should be referred to an ophthalmologist, urgently if there is visual loss.

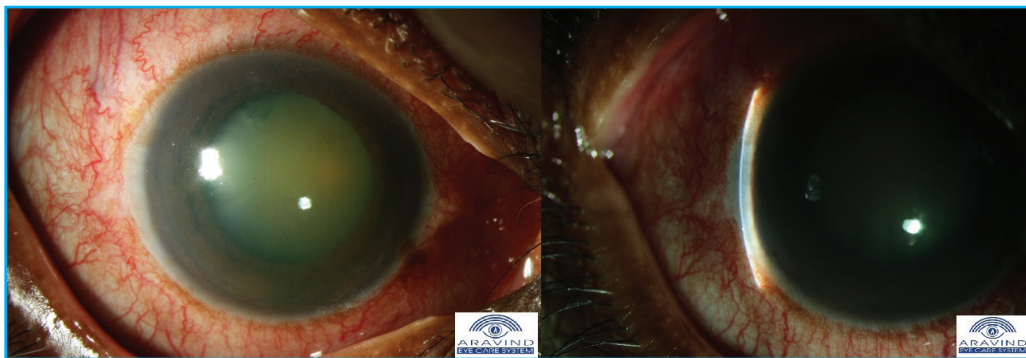
**Use of topical steroids for long term is harmful for the eye, as it may cause glaucoma, corneal ulcers and cataract.**

## CHAPTER - 10

# COMMON EYE CONDITIONS – GLAUCOMA

### 10.1 Acute Angle-Closure Glaucoma

**Primary acute angle-closure glaucoma** (acute angle-closure crisis) results from closure of a pre-existing narrow anterior chamber angle. The factors predisposing to the narrow angle are shallow anterior chamber, which may be associated with farsightedness or short stature (or both); enlargement of the crystalline lens with age causing further shallowing; and inheritance. Closure of the angle is precipitated by pupillary dilation and thus can occur from sitting in a darkened theatre, during times of stress, following non-ocular administration of anticholinergic or sympathomimetic agents (e.g., nebulized bronchodilators, atropine for preoperative medication, antidepressants, bowel or bladder antispasmodics, nasal decongestants, or tocolytics) or, rarely, from pharmacologic mydriasis.



*Acute Angle-Closure Glaucoma*  
*Source- Aravind Eye Hospital, Madurai*

**Secondary acute angle-closure glaucoma**, does not require a preexisting narrow angle, may occur in anterior uveitis or dislocation of the lens or due to various drugs. Symptoms are the same as in primary acute angle-closure glaucoma, but differentiation is important because of differences in management.

**Clinical Findings:** Patients with acute glaucoma usually seek immediate treatment with **extreme pain and blurred vision**. The blurred vision is typically associated with halos around lights. Nausea and abdominal pain may occur. The **eye is red, cornea cloudy, and the pupil moderately dilated** and nonreactive to light. Intraocular pressure is usually over 50 mm Hg, producing a hard eye on palpation.

**Differential Diagnosis:** Acute glaucoma must be differentiated from conjunctivitis, acute uveitis, and corneal disorders.

**Treatment:** Patient with suspected acute angle-closure glaucoma must be urgently referred to the ophthalmologist.



Initial treatment in acute glaucoma is reduction of intraocular pressure. A single 500-mg intravenous dose of acetazolamide, followed by 250 mg orally four times a day, together with topical medications is usually sufficient. Osmotic diuretics, such as oral glycerin and intravenous urea or mannitol-the dosage of all three being 1-2 g/kg may be necessary if there is no response to acetazolamide.


**Prognosis:** Untreated acute angle-closure glaucoma results in severe and permanent visual loss within 2-5 days after onset of symptoms. Affected patients need to be monitored for development of chronic glaucoma.

## 10.2 Chronic Glaucoma:

Chronic glaucoma is characterized by gradually progressive excavation (“cupping”) and corresponding pallor of the optic disk with loss of vision progressing from slight visual field loss to complete blindness. The intraocular pressure is elevated due to reduced drainage of aqueous fluid through the trabecular meshwork. In normal-tension glaucoma, intraocular pressure is not elevated but the same pattern of optic nerve damage occurs.


Primary (chronic) open-angle glaucoma is usually bilateral. There is an increased prevalence in first -degree relatives of affected individuals and in diabetic patients. Secondary open-angle glaucoma may result from ocular disease, e.g. pigment dispersion, pseudo exfoliation, uveitis, or trauma; or corticosteroid therapy, whether it is intraocular, topical, systemic, inhaled, or administered by nasal spray.

**Clinical Findings:** Initially there may be no symptoms. Abnormalities in at two of three parameters: optic disk or retinal nerve fiber layer (or both), visual field, and intraocular pressure suggests the diagnosis. Optic disk cupping is identified as an absolute increase or an asymmetry between the two eyes of the ratio of the diameter of the optic cup to the diameter of the whole optic disk (cup-disk ratio). **(Cup-disk ratio greater than 0.5 or an asymmetry between the eyes more of  $\geq 0.2$  is suggestive).** Fundus examination will lead to detection of optic disk cupping. Visual field abnormalities initially develop in the paracentral region, followed by constriction of the peripheral visual field. Central vision remains good until late in the disease. The normal range of intraocular pressure is 10-21 mm Hg. In many individuals, elevated intraocular pressure is not associated with optic disk or visual field abnormalities (ocular hypertension).



Source- Dr. Rajendra Prasad Centre for Ophthalmic Sciences

**Prevention:** Screening for chronic open-angle glaucoma should be targeted for individuals with an affected first-degree relative of patients with glaucoma and persons who have diabetes



mellitus. Screening may also be warranted in patients taking long-term corticosteroid therapy. Confirmed cases should be referred to an Eye Specialist/Eye Doctor for medical treatment and further management.

**Treatment:** Should be started in consultation with ophthalmologist. Prostaglandin analog eye drops are commonly used as first-line therapy. They may produce conjunctival hyperemia, permanent darkening of the iris and eyebrow color, increased eyelash growth, and reduction of periorbital fat (prostaglandin-associated periorbitopathy) which should be monitored. Brimonidine (selective alpha-2-agonist) may cause uveitis. In primary open-angle glaucoma- and if treatment is required in ocular hypertension-the aim is to reduce intraocular pressure to a level that will adequately reduce progression of visual field loss. In eyes with marked visual field or optic disk changes, intraocular pressure must be reduced to less than 16 mm Hg. In normal-tension glaucoma with progressive visual field loss, it is necessary to achieve even lower intraocular pressure such that surgery is often required.

**Prognosis:** Untreated chronic glaucoma that begins at age 40-45 years will probably cause complete blindness by age 60-65 years. Early diagnosis and treatment can preserve useful vision throughout life.

**When to Refer:** All patients with suspected chronic glaucoma should be referred to an ophthalmologist.



# CHAPTER - 11

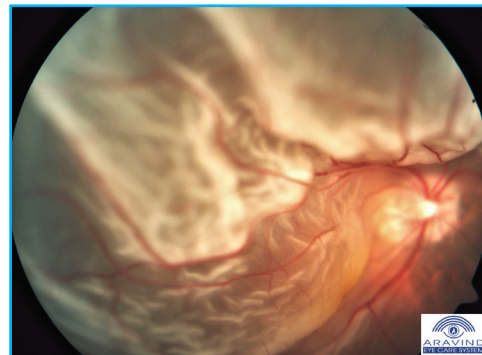
## EYE CONDITIONS AFFECTING POSTERIOR SEGMENT OF EYE

### 11.1 Retinal Detachment

Usually caused by development of retinal tear or holes (rhegmatogenous retinal detachment). It is usually spontaneous, related to degenerative changes in the vitreous, and generally occurs in persons over 50 years of age. Nearsightedness and cataract extraction are the two most common predisposing causes.

Tractional retinal detachment is more common in proliferative diabetic retinopathy. Age-related macular degeneration (ARMD) can also cause retinal detachment due to fluid accumulation behind retina (Serous/Exudative retinal detachment).

Retinal detachment may also be caused by penetrating or blunt ocular trauma.



*Retinal Detachment*  
Source- Aravind Eye Hospital, Madurai

**Clinical features:** Rhegmatogenous retinal detachment usually starts in the superior temporal area, spreading rapidly to cause visual field loss that starts inferiorly and expands upwards. Recent onset of or increase in floaters (moving spots or streaks in the visual field) and photopsias (flashes of light) may be associated with incipient retinal detachment. Central vision remains intact until the macula becomes detached. On ophthalmoscopic examination/fundal image, the retina is seen hanging in the vitreous like a gray cloud. Retinal tears or holes (or both) will usually be also found on further examination. In traction retinal detachment, there is irregular retinal elevation. In serous retinal detachment, the retina is dome-shaped and the subretinal fluid shifts position with changes in posture. Loss of vision in one eye that is usually rapid, possibly described as a “curtain” spreading across field of vision. No pain or redness are the usual clinical features associated with retinal detachment.

**What to do:** Refer to ophthalmologist urgently.

### 11.2 Vitreous Haemorrhage

**Clinical presentation:** Patients with vitreous hemorrhage complain of sudden visual loss, abrupt onset of floaters that may progressively increase in severity, or occasionally ‘bleeding within the eye’: Visual acuity ranges from very low vision to only light perception. The eye is not inflamed (not red), and fundal details are not seen on ophthalmoscopy or localized collection of blood in front of the retina may also be seen sometimes.

Causes of vitreous hemorrhage include retinal tear (with or without detachment), diabetic retinopathy, retinal vein occlusion, retinal vasculitis, neovascular age-related macular degeneration, therapeutic anticoagulation, trauma, subarachnoid hemorrhage, and severe straining.

**What to do:** Refer to ophthalmologist urgently.

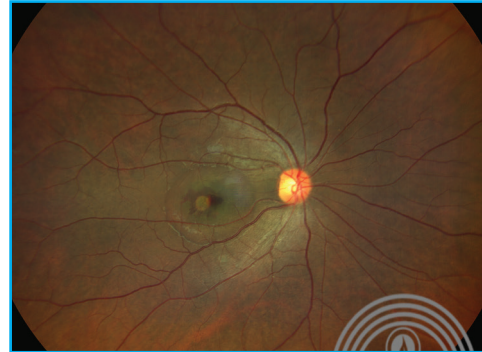### 11.3 Age-Related Macular Degeneration (ARMD):

Age-related macular degeneration is one of the leading cause of permanent visual loss in the older population. Associated risk factors are increasing age, sex (slight female predominance), family history, cigarette smoking. ARMD results primarily in loss of central field vision. Therefore, peripheral fields help maintain navigational vision in these patients.

Age-related macular degeneration is classified into dry ARMD (“atrophic”; “geographic”) and wet ARMD (“neovascular”; “exudative”). Both of these are progressive and usually bilateral, however the prognosis of wet ARMD is considerably worse.

The precursor to ARMD is age-related maculopathy that is characterized by retinal drusen. Hard drusen appear ophthalmoscopically as discrete yellow deposits. Soft drusen are larger, paler, and less distinct. Large, confluent soft drusen are particularly associated with neovascular (wet) age-related macular degeneration.

**Management:** There is no specific treatment for atrophic degeneration, but patients may benefit from low-vision aids. Control of diabetes and encouraging people to stop smoking may help prevent the disease. Patient suspected to have ARMD should be referred to ophthalmologist for assessment and initiation of management.



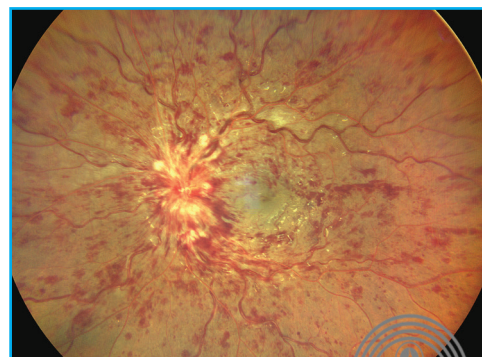
*Age-Related Macular Degeneration (ARMD)  
Source- Aravind Eye Hospital, Madurai*

### 11.4 Central and Branch Retinal Vein Occlusions:

**Clinical presentation:** Patient presents with sudden monocular loss of vision not associated with complaint of pain or redness. On ophthalmoscopic examination optic disc swelling, retinal venous dilation and tortuosity and widespread or sectoral retinal hemorrhages (cotton wool spots) may be seen.

**Risk factor**—Age more than 65 years, Hypertension, Hyperlipidemia, raised IOP, smoking and use of combined contraceptive pills in women. Also screen for diabetes mellitus.

**What to do:** Refer urgently to the ophthalmologist.



*Central and Branch Retinal Vein Occlusions  
Source- Aravind Eye Hospital, Madurai*

### 11.5 Central and Branch Retinal Artery Occlusions:

Diabetes mellitus, hyperlipidemia, and systemic hypertension are common risk factors. History of migraine and use of oral contraceptives should be elicited as they may be associated with it.

**Clinical presentation:** Central retinal artery occlusion presents as sudden profound monocular visual loss. Visual acuity is usually reduced to counting fingers or worse, and visual field is restricted to an island of vision in the temporal field. Ophthalmoscopy reveals pallid swelling of the retina with a cherry-red spot at the fovea. The retinal arteries are attenuated, and “box-car” segmentation of blood in the veins may be seen.

**What to do:** Patients with central retinal artery occlusion should be referred emergently to an ophthalmologist on oxygen and making patient lie flat during transportation.

## 11.6 Transient Monocular Visual Loss:

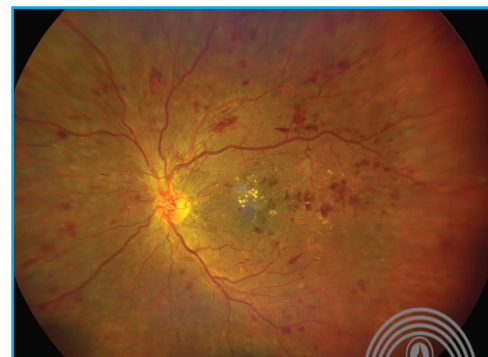
**Clinical presentation:** Transient monocular visual loss is usually caused by a retinal embolus from ipsilateral carotid disease or the heart. The visual loss is characteristically described as a curtain passing vertically across the visual field with complete monocular visual loss lasting a few minutes and a similar curtain effect as the episode passes (amaurosis fugax; “fleeting blindness”). An embolus is rarely seen on ophthalmoscopy. Other causes of transient, often recurrent, visual loss due to ocular ischemia are giant cell arteritis, hypercoagulable state (such as antiphospholipid syndrome), hyperviscosity, and severe occlusive carotid disease. In young patients, a benign form of transient recurrent visual loss ascribed to choroidal or retinal vascular spasm can occur.

**Management:** All patients with possible embolic transient visual loss should be treated immediately with oral aspirin daily (150mg), or another antiplatelet drug, until the cause is determined. Hypertension should be controlled. Referral to ophthalmologist.

## 11.7 Retinal Disorders Associated with Systemic Diseases:

### a) Diabetic Retinopathy (DR):

Retinopathy increases in prevalence and severity with increasing duration and poorer control of diabetes. Non-proliferative retinopathy manifests as microaneurysms, retinal hemorrhages, venous beading, retinal edema, and hard exudates which can be seen ophthalmoscopy. Diminution of vision in DR is often due to diabetic macular edema. Proliferative DR is characterized by neovascularization, arising from either the optic disk or the major vascular arcades. Vitreous hemorrhage is a common sequela.



*Diabetic Retinopathy*  
Source- Aravind Eye Hospital, Madurai

Visual symptoms and visual acuity are poor indicators of the presence of diabetic retinopathy. Adult and adolescent patients with diabetes mellitus should undergo at least yearly screening by fundal photography. Patients with type 2 diabetes mellitus must be screened at the time of diagnosis (or shortly thereafter).

**Management** at primary level includes blood glucose control, maintaining normal blood pressure, optimizing kidney function and serum lipids. These measures have probably more importance in preventing the development of retinopathy than in influencing its subsequent course.

**Referral** to ophthalmologist for periodic fundus examination (every year) and treatment of any complications. All diabetic patients with sudden loss of vision or retinal detachment should be referred emergently to an ophthalmologist. Proliferative retinopathy or macular involvement requires urgent referral to an ophthalmologist. Severe non-proliferative retinopathy or unexplained reduction of visual acuity requires early referral to an ophthalmologist.

**b) Hypertensive Retinochoroidopathy:**

**Clinical presentation:** The clinical manifestations vary according to the degree and rapidity of rise in blood pressure and the underlying state of the ocular circulation. The most extensive ocular changes occur in young patients with abrupt elevations of blood pressure, such as may occur in pheochromocytoma, malignant hypertension, or preeclampsia-eclampsia. Hypertensive retinopathy can be a surrogate marker for current and future non-ocular end organ damage.

**On fundus examination:** In chronic hypertension tortuous and narrow retinal arterioles with abnormal light reflexes (“silver-wiring” and “copper-wiring”) can be seen. Increased venous compression at the retinal arteriovenous crossings are seen as “arteriovenous nicking”. Flame-shaped hemorrhages occur in the nerve fiber layer of the retina. In acute hypertension, cotton-wool spots, retinal hemorrhages, retinal edema, and retinal exudates, often in a stellate appearance at the macula can be seen. Fundal abnormalities are the hallmark of hypertensive crisis with retinopathy.

**What to do:** Immediate Blood Pressure control. Refer urgently to an ophthalmologist.

## 11.8 Ischaemic Optic Neuropathy:

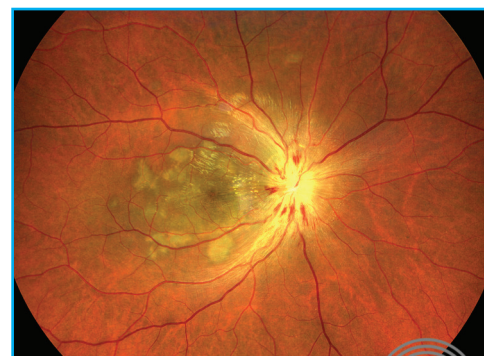**Clinical presentation:** Sudden painless visual loss with signs of optic nerve dysfunction, optic disk swelling in anterior ischemic optic neuropathy may also be seen on fundus examination.

Risk factors include systemic hypertension, diabetes mellitus, hyperlipidemia, systemic vasculitis, inherited or acquired thrombophilia, interferon-alpha therapy, obstructive sleep apnea.

**Clinical presentation:** For management refer the patient urgently to the ophthalmologist.

## 11.9 Optic Neuritis:

**Clinical presentation:** Optic neuritis is characterized by unilateral loss of vision developing over a few days. Visual acuity ranges from (6/9) to no perception of light. Almost always there is pain behind the eye, exacerbated by eye movements. Visual field loss is usually central. There is typical defect in color vision and a relative afferent pupillary defect (RAPD). In about two-thirds of cases, the optic nerve is normal during the acute stage (retrobulbar optic neuritis). In the remainder, the optic disk is swollen (papillitis) with occasional



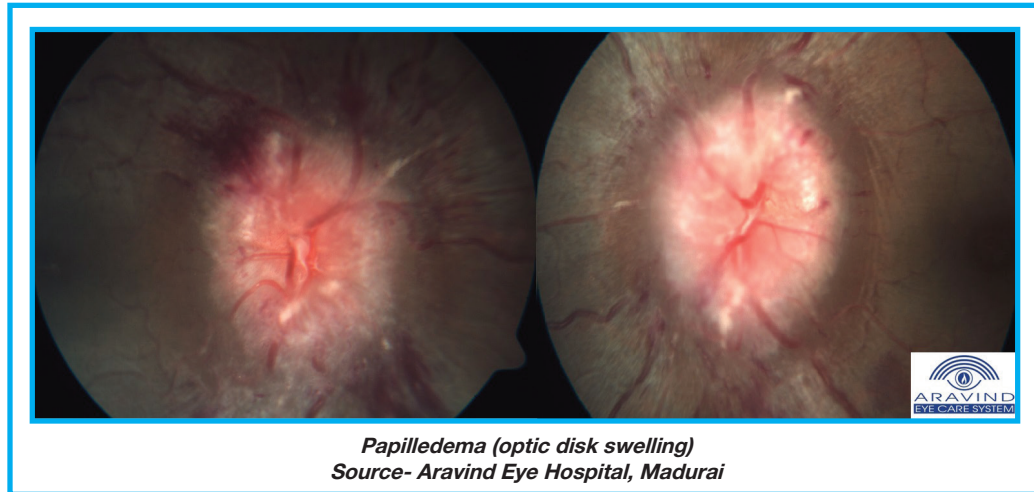
*Optic Neuritis*  
Source- Aravind Eye Hospital, Madurai



flame-shaped peripapillary hemorrhages. Visual acuity usually improves within 2-3 weeks and returns to (6/12) or better in vast majority of the previously unaffected eyes. Optic atrophy may subsequently develop.

**Clinical presentation:** For management refer the patient urgently to the ophthalmologist.

### 11.10 Optic Disk Swelling:



Optic disk swelling may result from intraocular disease, orbital and optic nerve lesions, severe hypertensive retinopathy, or raised intracranial pressure. Intraocular causes include central retinal vein occlusion, posterior uveitis, and posterior scleritis. Optic nerve lesions causing disk swelling include anterior ischemic optic neuropathy; optic neuritis; optic nerve sheath meningioma; and infiltration by sarcoidosis, leukemia, or lymphoma. Any orbital lesion causing nerve compression may produce disk swelling. Papilledema (optic disk swelling due to raised intracranial pressure) is usually bilateral and most commonly produces enlargement of the blind spot without loss of acuity. Chronic papilledema, as in idiopathic intracranial hypertension and cerebral venous sinus occlusion, or severe acute papilledema may be associated with visual field loss and occasionally with profound loss of acuity. All patients with chronic papilledema must be monitored carefully.

**What to do:** Refer patient to ophthalmologist/ neurologist for management.



# CHAPTER - 12

## MISCELLANEOUS EYE CONDITIONS

### 12.1 Ocular Motor Palsies:

**Clinical presentation:** In complete third nerve paralysis, there is ptosis with a divergent and slightly depressed eye. Extraocular movements are restricted in all directions except laterally. Fourth nerve paralysis causes upward deviation of the eye with failure of depression on adduction. Sixth nerve paralysis causes convergent squint in the primary position with failure of abduction of the affected eye, producing horizontal diplopia that increases on gaze to the affected side and on looking into the distance.

**What to do:** Any patient with recent onset isolated third nerve palsy, particularly if there is pupillary involvement or pain, must be referred emergently for neurologic assessment. All patients with recent onset double vision should be referred urgently to an ophthalmologist or neurologist, particularly if there is multiple cranial nerve dysfunction or other neurologic abnormalities.

### 12.2 Thyroid Eye Disease (Graves Ophthalmopathy):

It usually occurs in association with autoimmune hyperthyroidism. Radioiodine therapy, and cigarette smoking increase the severity of thyroid eye disease.

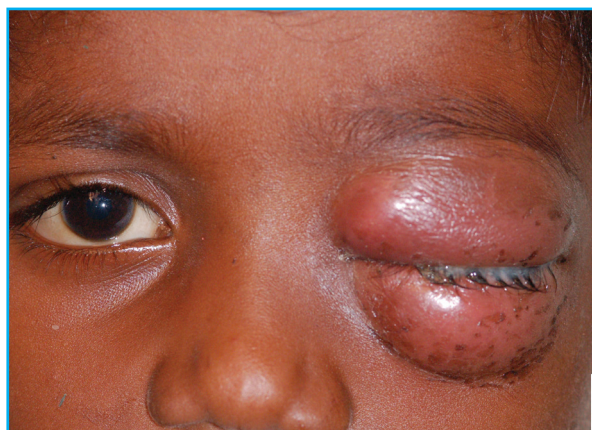**Clinical presentation:** The clinical features are proptosis, lid retraction and lid lag, conjunctival chemosis and episcleral inflammation, defective vision and extraocular muscle dysfunction. Resulting symptoms are cosmetic abnormalities, surface irritation, which usually responds to artificial tears, and diplopia, which should be treated conservatively (e.g., with prisms) in the active stages of the disease. The important complications are sequelae of corneal exposure and optic nerve compression.

**What to do:** Patient with moderate-to severe disease should be referred to ophthalmologist for advice or if vision is diminished urgent referral should be made.

### 12.3 Orbital Cellulitis:

**Clinical presentation:** Orbital cellulitis is characterized by fever, proptosis, restriction of extraocular movements, and swelling with redness of the lids.

**What to do:** All patients with suspected orbital cellulitis must be referred urgently to an ophthalmologist.



*Orbital Cellulitis*  
Source- Aravind Eye Hospital, Madurai

## CHAPTER - 13

# CERTIFICATION OF VISUAL IMPAIRMENT, BLINDNESS

### 13.1 Definitions of Visual impairment

**This definition is for Disability Certification**

1. “Blindness” means a condition where a person has any of the following conditions, after best correction
  - i. total absence of sight; or
  - ii. visual acuity less than 3/60 (10/200) in the better eye with best possible correction; or
  - iii. Limitation of the field of vision subtending an angle of less than 10 degree.
2. “Low-vision” means a condition where a person has any of the following conditions:
  - i. visual acuity not exceeding 6/18 (20/60) up to 3/60 (10/200) in the better eye with best possible corrections; or
  - ii. Limitation of the field of vision subtending an angle of less than 40 degree up to 10 degree.

### 13.2 Disability Certification

Certificate for Blindness and Visual Impairment can be issued by the Medical Officer (AB-HWC-PHC/UPHC) in consultation with an Eye Doctor/ Eye Specialist to any individual who fits the definition of Blindness or Visual Impairment. The certificate may be temporary or permanent based on the type of disability. The certificate can be temporary if condition is likely to worsen and also for specific purposes such as for pursuing education. The need of reassessment, if required, should be clearly mentioned in the certificate with time frame. In certain cases, such as developmental defects, operated congenital cataract with corneal decompensation, operated congenital glaucoma with hazy cornea etc., the patient especially can be issued a temporary certificate.

The certification of visual disability or blindness should done with great care and responsibility as this certificate is a legal document. In case of any doubt, it is better to refer the patient to an ophthalmologist at district level.

### 13.3 Visual Impairment Certification Criteria and Gradation:

**Vision assessment should be done after best possible correction (medical, surgical or usual/conventional spectacles).** You shall circle the Vision Status and the Percentage Impairment and mark the Disability category accordingly as given in the table below.

**Table 5: Visual Impairment Certification Criteria**

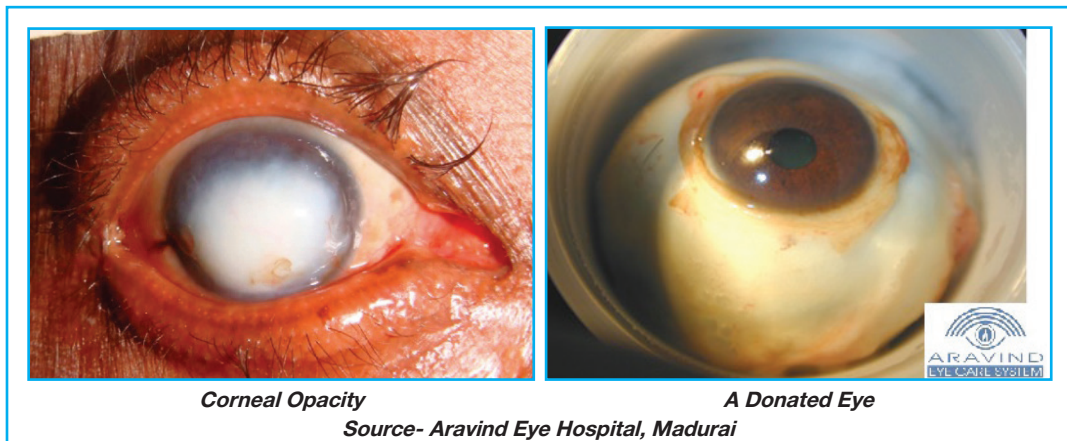
Better eye Best Corrected	Worse eye Best Corrected	Per cent Impairment	Disability category
6/6 to 6/18	6/6 to 6/18	0 %	0
	6/24 to 6/60	10%	0
	Less than 6/60 to 3/60	20%	I
	Less than 3/60 to No Light Perception	30%	II (one eyed person)
6/24 to 6/60 OR Visual field less than 40 up to 20 degree around centre of fixation OR heminaopia involving macula	6/24 to 6/60	40%	IIIa (low vision)
	Less than 6/60 to 3/60	50%	IIIb (low vision)
	Less than 3/60 to No Light Perception	60%	IIIc (low vision)
Less than 6/60 to 3/60 OR Visual field less than 20 up to 10 degree around centre of fixation	Less than 6/60 to 3/60	70%	IIId (low vision)
	Less than 3/60 to No Light Perception	80%	IIIe (low vision)
Less than 3/60 to 1/60 OR Visual field less than 10 degree around centre of fixation	Less than 3/60 to No Light Perception	90%	IV a (Blindness)
Only HMCf Only Light Perception, No Light Perception	Only HMCf Only Light Perception, No Light Perception	100%	IV b (Blindness)

\* HMCf - Hand movement close to face; For Visual acuity the line should be read completely, in case of partial line read, one line below that line should be taken for visual acuity.

# CHAPTER - 14

## EYE DONATION

The front transparent portion of the eye that covers pupil is called as cornea. In certain conditions, it becomes opaque and it leads to corneal blindness. Persons affected with same, can get rid of their blindness by replacing with a healthy cornea tissue. **Donating the eyes after death of the individual is referred as 'Eye Donation'.**



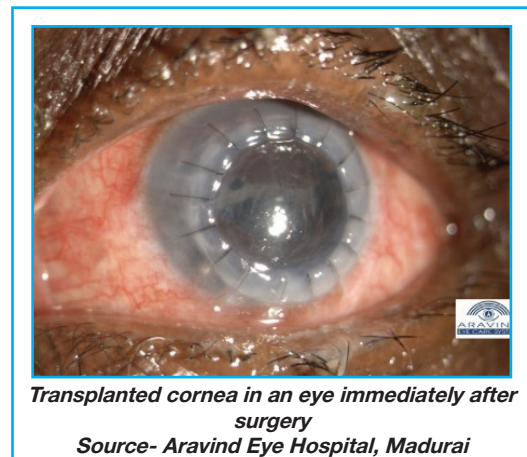
Eye donation is an act when one person can donate their eyes to persons who suffering from corneal blindness. An eye donation helps 3-4 persons to regain their vision.

There is a huge demand and the supply is not sufficient for the people who need it. Thus, as a society, we need to come forward for this noble cause and help our community. You should encourage community members to understand this and agree to donate their eyes after their death.

Very often the individual usually agrees, but the relatives have a problem after their death. There is no cost involved in eye donation as even person receiving the cornea, does not have to pay any amount. It is a voluntary act and is free of cost. A person of any age, sex, religion, caste can donate his/her eyes. Donated eyes are never bought or sold. In your target area, people with diabetes, hypertension and asthma can also donate their eyes after their death.

The eyes can be donated at home or hospital after death. The Eyes/corneas are taken out by the trained team within 6 hours of death, beyond which time, eyes cannot be donated. For those ready to donate their eyes, the relatives must call up the nearest eye bank at **National toll-free number (24X7) – 1800114770 and 1919 (for metro cities)**. On receiving the call, the team members will visit them within 6 hours of death and collect the Eyes/Corneas.

The Eye retrieval team may either remove whole eye or only front portion of the eyes, that is, the corneoscleral rim from the dead body. It does not lead to any defect of the face.



CHO/MO heading the nearest AB-HWCs is responsible for creating awareness generation on eye donation and will be supported by the primary healthcare team, Village Health, Sanitation and Nutrition Committee (VHSNC) members, Mahila Arogya Samiti (MAS) members, support groups, etc. in motivating community members for eye donation.

With support of the primary healthcare team, explain to the community that pledging for eye donation can be done by anyone in their lifetime. Persons who have pledged their eyes, must inform their family members regarding the pledge, as they would be able to contact the nearest eye bank after one's death. Even if the pledge has not been done, the family members can still call the eye bank and can get the eyes of the deceased person donated. Any person can donate their eyes; even those who have undergone any eye operation or have any eye disease condition except those with Hepatitis, Human Immunodeficiency Virus (HIV), rabies, blood cancers or stage IV cancers.

#### **Precautions to be taken after death for donation of eyes**

The family members should take care that there is no wind or breeze where the body of the deceased (dead person) is kept, and the fan should be switched off in that room. This will prevent drying of the eye. The head of the deceased person should be supported by pillow, eyelids should be closed and eyes can be covered with moist cotton piece or ice. This will enable corneas of the eye to remain fresh for donation.

#### **Some Myths and Facts about Eye Donation**

1. **MYTH:** Removal of eyes causes defect of the face.  
**FACT:** Removal of eyes does not produce any defect of the face.
2. **MYTH:** Eye donation interferes with, or delays customary final rites.  
**FACT:** Eye donation does not interfere with or delay final rites, as the process of taking the whole eye out of the face takes less than 20 minutes.
3. **MYTH:** Eyes of aged donors are not acceptable.  
**FACT:** All donor eyes are acceptable irrespective of donor's age, including eyes of premature/ still born babies.
4. **MYTH:** An entire eye can be transplanted.  
**FACT:** Only the cornea can be transplanted for regaining vision.
5. **MYTH:** Human eyes can be bought or sold.  
**FACT:** Selling or buying of human eyes is illegal.

#### **Role of MO in Eye Donation**

1. Along with the primary healthcare team, VHSNC members, MAS members, support groups, etc. help motivating community members for Eye donation.
2. Organize community meetings to educate people about Eye donation.
3. Organize pledge ceremonies on important village days/ festivals about Eye donation. Remember, every year, August 25th to September 8th is observed as National eye donation fortnight all over our country.
4. Facilitate whenever required, for willing family to donate eyes of the deceased persons and make necessary arrangements.



## CHAPTER - 15

# SERVICE DELIVERY FRAMEWORK AND ROLES AND RESPONSIBILITIES OF MEDICAL OFFICER (AB-HWC-PHC/UPHC) IN EYE CARE

As a Medical Officer (AB-HWC-PHC/UPHC), you should provide leadership, supportive supervision and coordinate the activities of the team at your AB-HWC and all the AB-HWC-SHCs in your area. You should communicate regularly with the teams at all the AB-HWC-SHC (CHOs, ANM/MPWs, ASHA Facilitators, ASHAs) and your team at the AB-HWC-PHC/UPHC (Staff Nurse, ANM/MPW, ASHAs) and Ophthalmic Assistant at Vision Centres. You should ensure:

- All ASHA, ANM/MPW, CHO, Staff Nurse are trained as per requirements for efficient and good quality eye care services provision,
- Work division is clear and non-overlapping,
- All members work as team and any friction/ issue is resolved amicably,
- Each team member maintains records properly.

Your clinical role with respect to eye care services at the AB-HWC-PHC/UPHC is to provide primary eye care to the patients arriving at your centre and the patients referred to you from the AB-HWC-SHCs, and also refer complicated cases and cases requiring surgery to higher health centres and follow-up the referred cases in the community. You will also coordinate activities for screening of your population for refractive errors and common eye disorders including Vitamin A deficiency, coordinate with the Rashtriya Bal Swasthya Karyakram (RBSK) team for screening of population 0-18 years of age, and coordinate the provision of spectacles to those who need it. You will also be in charge of inventory control and maintaining the required records and reports at your health centre. The Staff Nurse will assist you in undertaking the activities.

The table below summarizes the eye health care services that are to be provided at different levels. It will help you to understand the range of services that need to be provided at each level and how to strengthen the continuum of care and referral linkages.

## Service Delivery Framework for Eye Care Services

Care at Community Level	Care at AB-HWC-SHC	Care at AB-HWC-PHC/UPHC	Care at Vision Centre/Secondary/ Tertiary care facility
<ul style="list-style-type: none"> <li>Awareness generation on common eye disorders and the need for early care seeking through VHSNC/MAS, VHSND/UHSND and other community level meetings <b>(ASHA/AF/MPW)</b>.</li> <li>Clarifying misconceptions related to eye care and eye disorders <b>(ASHA/AF/MPW)</b>.</li> <li>Providing Information about the availability of services related of eye treatment at different levels of healthcare <b>(ASHA/AF/MPW/ VHSNC/MAS)</b>.</li> <li>Screening of pre-term/ LBW newborns for congenital disorders and referral, children and adolescents through Anganwadis and schools for vision problems/visual acuity and adult population for blindness and refractive errors <b>(facilitated by ASHA/AF/MPW in coordination with RBSK team, where needed)</b>.</li> <li>Identification/Mobilization of patient with identified eye diseases (of known diabetic, identified patients) <b>(ASHA/AF/MPW)</b>.</li> <li>Ensuring Vitamin A prophylaxis routinely for children aged 6 months to 5 years <b>(ASHA/AF/MPW)</b>.</li> <li>Referral of patients with eye/vision problems to the nearest AB-HWC and follow-up <b>(ASHA/AF/MPW)</b>.</li> <li>Follow up of post-operative cataract patients and distribution of spectacles to them <b>(ASHA/AF/MPW)</b>.</li> </ul>	<ul style="list-style-type: none"> <li>Screening for blindness and refractive errors- Testing of visual acuity (distance and near vision), diagnosis of refractive errors and referral to Vision Centre of those requiring surgery/for management or treatment including provision of spectacles <b>(CHO/MPW)</b>.</li> <li>Identification of common diseases of the eye and referral to Vision centres – Cataract, corneal diseases, glaucoma, eye disorders in known diabetic/hypertensive patients <b>(CHO)</b>.</li> <li>Diagnosis and referral to MO at AB-HWC-PHC– conjunctivitis, trachoma, eye allergy, acute red eye, xerophthalmia <b>(CHO)</b>.</li> <li>Regular eye screening and coordination with RBSK team for screening children aged 0-18 years in AWC and schools <b>(CHO)</b>.</li> <li>To identify and treat Vitamin A deficiency and Bitot's spot; and provide Vitamin A prophylaxis <b>(CHO/MPW)</b>.</li> <li>Undertake home and community-based follow up visits; also, along with the ASHA/AF <b>(CHO/MPW)</b>.</li> <li>Health Promotion activities with use of IEC - Awareness generation about refractive disorders, common eye diseases, contagious eye diseases and infections and preventive care <b>(CHO/MPW)</b>.</li> </ul>	<ul style="list-style-type: none"> <li>The Medical Officer (MBBS) at the AB-HWC-PHC/UPHC would be responsible for ensuring that eye care services are delivered through all AB-HWCs in her/his area.</li> <li>Examination and diagnosis of all eye cases referred from community or AB-HWC-SHC <b>(MO)</b>.</li> <li>Diagnosis and treatment of common eye diseases like conjunctivitis, trachoma, refractive errors, dry eye, sty, superficial foreign body, eye allergy, acute red eye, xerophthalmia, etc. <b>(MO)</b>.</li> <li>Primary eye care for trauma <b>(MO)</b>.</li> <li>Screening for high-risk cases of glaucoma and referral to higher centres for early diagnosis and treatment <b>(MO)</b>.</li> <li>Screening for diabetic retinopathy, using non-mydiatic fundus camera and facilitating consultation with eye specialist at early stage with referral for further treatment <b>(MO)</b>.</li> <li>Referral for advice to eye specialist for corneal blindness and follow instructions given by specialist <b>(MO)</b>.</li> <li>Act as Nodal Officer for Vision Centre operations <b>(MO)</b>.</li> <li>Medical fitness for cataract surgery, disability certification (in consultation with an Eye doctor/Eye specialist), outreach activities, quality assurance of ASHA and OA activities <b>(MO)</b>.</li> <li>Surveillance of trachoma and referral to eye specialist where needed <b>(MO)</b>.</li> </ul>	<ul style="list-style-type: none"> <li>Eye Screening Camp- Assist district team during eye screening/outreach camps <b>(Ophthalmic Assistant- OA)</b>.</li> <li>Diagnosis for refractive errors and provision of free spectacles to patients diagnosed with presbyopia and school children with refractive errors <b>(OA)</b>.</li> <li>Collaboration with RBSK team to provide spectacles to children with refractive errors <b>(OA)</b>.</li> <li>Identification of operable cataract, screening for high-risk cases of glaucoma and referral to higher centres for early diagnosis and treatment; and follow-up of post-operative cases <b>(OA)</b>.</li> <li>Screening for diabetic retinopathy, using non-mydiatic fundus camera and facilitating consultation with eye specialist at early stage with referral for further treatment <b>(OA)</b>.</li> <li>Referral for advice to eye specialist for corneal blindness and follow instructions given by specialist <b>(OA)</b>.</li> <li>Referral to ophthalmologist for removal of corneal/deep foreign bodies in eye <b>(OA)</b>.</li> <li>Surveillance of trachoma and referral to eye specialist where needed <b>(OA)</b>.</li> <li>Surgical care for eye diseases like cataract, corneal blindness, trachoma, glaucoma, severe trauma to eye, corneal/deep lodgement of foreign body in eye, retinal disease <b>(Ophthalmologist)</b>.</li> </ul>

Service Delivery Framework for Eye Care Services			
Care at Community Level	Care at AB-HWC-SHC	Care at AB-HWC-PHC/UPHC	Care at Vision Centre/Secondary/ Tertiary care facility
<ul style="list-style-type: none"> <li>Ensure regular use of spectacles and follow-up bi-annually in children with refractive error <b>(ASHA/AF/MPW)</b>.</li> <li>Enabling elderly and those with Presbyopia to get free spectacles <b>(ASHA/AF/MPW)</b>.</li> <li>IEC for health promotion activities related to Eye Health; imparting health education to at-risk of visual impairment <b>(ASHA/AF/MPW)</b>.</li> <li>Maintenance of records of visually impaired/ blind individuals in the community <b>(ASHA/AF/MPW)</b>; maintaining a list of referrals from community who cannot count by finger counting method, read by 6/18 Snellen Vision Chart (E chart) and those at risk through CBAC <b>(ASHA)</b>.</li> <li>Undertake rehabilitation and counselling <b>(ASHA/AF/MPW)</b>.</li> </ul>	<ul style="list-style-type: none"> <li>Stabilization and referral of cases with trauma to the eye, chemical injury to eye, foreign body lodged in cornea to the higher health centres <b>(CHO)</b>.</li> <li>Dispensing of medicines for conjunctivitis, dry eye, Trachoma and follow-up medicines for chronic eye disease (e.g. Cataract, Glaucoma and Diabetes) treated at referral centre <b>(CHO)</b>.</li> <li>Awareness generation on eye donation, provide first aid for foreign body, eye injuries, stabilization and then referral <b>(CHO)</b>.</li> <li>Care of eye due to acid/alkali/chemical exposure and immediate referral <b>(CHO/MPW)</b>.</li> <li>Maintenance of records as per NPCB&amp;VI guidelines <b>(CHO)</b>.</li> </ul>	<ul style="list-style-type: none"> <li>Providing follow up care for post-operative cases as recommended by the eye specialist <b>(MO)</b>.</li> <li>Ensure record maintenance as per NPCB&amp;VI guidelines and periodic review of progress <b>(MO)</b>.</li> </ul>	<ul style="list-style-type: none"> <li>Treatment of vision disorders, eye diseases and infections <b>(Ophthalmologist)</b>.</li> <li>Record maintenance as per NPCB&amp;VI guidelines <b>(OA)</b>.</li> </ul>

**Key Roles and responsibilities of Medical Officer (MBBS) at Ayushman Bharat- Health and Wellness Centre- Primary Health Centre and Urban Primary Health Centre (AB-HWC-PHC/UPHC):**

1. The Medical Officer (MBBS) at the AB-HWC-PHC/UPHC would be responsible for ensuring that eye care services are delivered through all AB-HWCs in her/his area.
2. Diagnosis and treatment of common acute eye condition/infections and primary eye care for trauma presenting to the AB-HWC-PHC/UPHC and those referred from the AB-HWC-SHC.
3. Diagnosis for refractive errors and provision of free spectacles to patients diagnosed with presbyopia and school children with refractive errors (in collaboration with District NPCB&VI Officer).
4. Collaboration with RBSK team to provide spectacles to children with refractive errors.
5. Referral of more complex cases to CHC/Sub-District Hospital/District Hospital to an Eye Specialist/Eye Doctor and provide follow-up care as advised.
6. Provide medical fitness for cataract surgery and referral to higher health centres for surgery, follow- up care for operated patients.

7. Screening for high-risk cases of glaucoma and referral to higher centres for early diagnosis and treatment and provide follow-up care for operated patients.
8. Screening for diabetic and hypertensive retinopathy and facilitating consultation with eye specialist at early stage. Annual screening of all diabetic patients must be done.
9. Refer cases of corneal blindness to eye specialist and follow-up care for patients.
10. Primary treatment for eye injuries and removal of superficial foreign body in the eye. Referral to ophthalmologist for corneal/deep foreign bodies in the eye.
11. Coordination with district team/RBSK team for eye screening camps and outreach services.
12. Carry out surveillance of trachoma cases and refer to eye specialist where needed.
13. Coordinate health promotion activities related to eye health including counseling regarding eye hygiene, ensuring healthy diet, providing Vitamin A prophylaxis, awareness generation regarding available eye care services.
14. Nodal officer for Vision Centre operations, outreach activities (planning, monitor wellness clinics/community workers and co-ordination with district hospitals), quality assurance of ASHA and Ophthalmic Assistant (OA) in delivering Eye Care.
15. Ensure record maintenance as per NPCB&VI guidelines and periodic review of progress.
16. Supportive supervision of AB-HWC-PHC/UPHC team and AB-HWC-SHC teams in regular eye care activities.
17. Monitoring activities of your team in daily activities as well as in monthly meetings.
18. Maintenance of medicines and equipment and inventory control.

The Eye Specialist/Eye Doctor at higher health facilities would prescribe a treatment, which would be continued at community and AB-HWCs level. The patient would need to visit the Eye Specialist/Eye Doctor as per the instructions provided.

Refer to Annexure- 3 and Annexure-4 for correct steps to administer eye drops and eye ointment, respectively.

**The key role and responsibilities of different members of team at AB-HWC for Eye Care is listed below:**

**ASHA:**

1. To identify people with blindness and visual impairment in the service/coverage area. Prepare a line list of all those with poor vision including children and adults living in your service area.
2. Screening for blindness in the community by using finger counting method, visual impairment in the community using 6/18 vision chart for all adult community members and undertake the exercise of filling Community Based Assessment Checklist (CBAC) for target individuals. Refer Annexure-5 for Community Based Assessment Checklist (CBAC).
3. Mobilise individuals found at risk (unable to see with finger counting test, visual impairment less than 6/18 in any eye and with any symptom in CBAC form) for further screening at nearest AB-HWC.

4. Mobilise the mother/caregivers for eye examination for all children (including preterm and low birth weight children) and adolescents for screening for visual acuity at school and Anganwadi levels through RBSK team (0-18 years of age).
5. Create awareness in the communities regarding maintenance for personal hygiene and environmental and lifestyle modifications, avoid myths and misconception related to eye care and motivate for eye donation.
6. Create awareness in the communities on need for early care seeking for eye problems and help bring change in health seeking behaviour of patients and caregivers.
7. Educate communities about prevention and common treatment of eye diseases such as Refractive Error, Cataract, Trachoma, Diabetic Retinopathy, childhood blindness, etc. that can lead to visual impairment.
8. Monitor and encourage patients with eye problems to complete their treatment and coordinate with the AB-HWC.
9. Generate awareness in the communities and mobilize children for Vitamin A prophylaxis and measles immunization.
10. Promote people with chronic conditions like diabetes and hypertension in getting their annual eye examinations and mobilize them to visit the nearest AB-HWC.
11. Assist in organizing community outreach eye care activities such as eye camps through AB-HWC. Provide support in mobilizing community members for attending eye screening camps organized in the community.
12. Utilize community-based platforms like through VHSNC/MAS, Village Health, Sanitation and Nutrition Day (VHSND)/Urban Health, Sanitation and Nutrition Day (UHSND) and other community level meetings for health talk fixed for eye care; impart information about basic eye care of the newborn to the pregnant and lactating women and caregivers.
13. Inform people with blindness and uncorrected refractive errors about financial schemes and benefits for their uptake, if found to be eligible.
14. Identify individuals in community for simple condition such as conjunctivitis (red eye), sty (swelling of eyelid), night blindness, difficulty in seeing or any other eye complaint and refer identified cases with eye/vision problems to the nearest AB-HWC for a proper check-up by the healthcare staff.
15. Ensure follow-up of patients requiring long term medication for diseases like glaucoma, diabetic retinopathy, post-operative patients, etc. through home visits.
16. Distribution of free spectacles to of post-operative cataract patients, enable the elderly with Presbyopia to get free spectacles and ensure regular use of spectacles in children with refractive error.
17. Rehabilitation by counselling people about role of family in supporting visually impaired and blind individual.

The ASHA Facilitators along with MPW/ANM, will mentor and provide support to the ASHAs in undertaking the above listed activities.

### **Auxiliary Nurse Midwife/Multi-Purpose Worker (ANM/MPW):**

1. Role in outreach as well as AB-HWC based activities.
2. Support and supervise the ASHA in undertaking her activities related to eye care. Undertake joint household visits with ASHAs for cross verification of 10% population.



3. Assist and support the CHO in providing eye care services in AB-HWC-SHC.
4. Support CHO in screening of individuals identified as high-risk by ASHA through finger counting method, 6/18 Snellen vision chart (E chart) and risk assessment through CBAC for visual acuity by using Snellen's Chart and near Vision card. Along with the ASHA, will ensure that all babies (including preterm and low birth weight children) and adolescents (0-18 years) undergo screening of vision and examination of the eye by the RBSK team at Anganwadi centres and schools. Provide support to the RBSK team. Inform parents about the screening, mobilize them and accompany them, if required for eye examination. Ensures follow-up care of such children on a regular basis as advised by the referral centre.
5. Help in case identification for Cataract, Presbyopia, Trachoma and Corneal disease.
6. Identify Vitamin A deficiency and Bitot's spot and assure Vitamin A prophylaxis.
7. Help in providing first aid for acid/alkali/chemical exposure under the guidance of the CHO.
8. Explain the community members about the availability of services related of eye treatment at different levels of healthcare.
9. Ensure regular use of spectacles in children with refractive error and enabling elderly and those with presbyopia and cataract to get free spectacles.
10. Identify suspected cases with eye/vision problems and inform the CHO for referral of complex cases to the appropriate facility as per the case. Assist the CHO in arranging referral.
11. Follow up care to patients, as advised by the referral centre during home visits or during their visit to AB-HWC for ensuring compliance to treatment, patients are not experiencing any complications, maintaining all required hygienic practices, responding to the treatment, etc. Do regular eye check-ups to look for any complication as well as advise the person for proper eye care.
12. Assist in organizing community outreach eye care activities such as eye camps through AB-HWC. Provide support in mobilizing community members for attending eye screening camps organized in the community.
13. Conduct health promotion activities along with the AB-HWC team- Vitamin A Prophylaxis, basic eye care, maintenance for personal hygiene and environmental cleanliness and lifestyle modifications, screening and early detection of problems as soon as any symptoms come, awareness generation about refractive disorders, common eye diseases, contagious eye diseases and infections and preventive care, teaching correct method of putting eye ointment/eye drops to community members, regular eye check-up and follow up of all referred cases, etc.
14. Along with CHO, help in educating school teachers and Anganwadi Workers (AWW) about the causes and prevention of common eye problem, identification of visual impairment among children and special needs of children with eye problems, including blind children.
15. Support the CHO in record keeping and reporting of information related to eye care/ disorders. Compilation and submission of timely reports related to eye care.
16. Support the CHO in stock management for eye related medicines and equipment.
17. Along with ASHA and ASHA Facilitator, help in clarifying misconceptions related to eye care and eye disorders in the community.

18. Along with the ASHA Facilitator, help in providing community-based rehabilitation, social acceptance and vocational training and inclusive education for low vision patients.

**Community Health Officer (CHO) at Ayushman Bharat- Health and Wellness Centre- Sub Health Centre (AB-HWC-SHC):**

1. The Primary Health Care team will be led by a Community Health Officer (CHO) at AB-HWC-SHC.
2. Ensures that regular eye screening is undertaken, coordinates with the RBSK team for screening children of age group 0-18 years in the Anganwadi and schools, manage the referral of those requiring surgery and treatment of refractive errors, ensure access to free spectacles, and would also undertake home and community-based follow up visits.
3. Make monthly action plans for health promotion activities including eye care messaging for the primary health care team.
4. Participate in VHSNC meetings, VHSND, health promotion campaigns, and school programmes and ensures that eye health promotion activities are carried out. Educate school teachers and AWW about causes and prevention of common eye problem, identification of visual impairment among children and special needs of children with eye problems, including blind children.
5. Conduct screening and basic management of common eye problems at special camps and focus on prevention messages. Motivate community for Eye Donation.
6. Counsel the identified patients for cataract surgery.
7. Regular monitoring of blood pressure and blood sugars of the community members aged 30 years and above.
8. Dispense medications as prescribed by the MO at AB-HWC-PHC or Eye Specialist/Eye Doctor.
9. Undertake the task of referrals of individuals to appropriate health facility during home visits and AB-HWC-SHC visits- such as of suspected/complex cases with eye problems, cataracts or eye complications of diabetes, etc. Must ensure that the MO is informed regarding any referral made to any health facility.
10. Provide follow-up care in coordination with the primary healthcare team members.
11. Arrange for rehabilitation for those with long term and permanent blindness including vocational rehabilitation, re- integration into school, etc.
12. Stock management for eye related medicines and equipment.
13. Maintenance of registers and records related to eye health.

MPW/ANM will assist the CHO in undertaking the tasks related to Eye Care at the AB-HWC-SHC.

### **Staff Nurse at Ayushman Bharat- Health and Wellness Centre- Primary Health Centre and Urban Primary Health Centre (AB-HWC -PHC/UPHC):**

Staff nurse may be tasked with the following roles by the Medical Officer In-charge:

1. Assist and support the Medical Officer at AB-HWCs in rural and urban areas in ensuring that eye care services are delivered at AB-HWCs. Work under his/her guidance in providing eye care services to the community members.
2. Help the Eye Care Team with screening at any of the screening camps organized under the AB-HWCs.
3. Support Medical Officer in screening of all population visiting the AB-HWCs for early identification of eye problems.
4. Can help in plan of the awareness programme, preparation of Information, Education and Communication (IEC) material required and arrange for audio-visual aids to assist in the health promotion activities at the AB-HWCs or in the field along with the AB-HWC team members.
5. Generate awareness amongst the individuals visiting AB-HWCs regarding maintaining good eye hygiene, eating a healthy diet, maintaining good sanitation, information regarding common eye problems, importance of early care-seeking and eye care services available at AB-HWCs.
6. Doing some minor procedures - irrigation of eyes, applying eye patch for eye protection, instilling eye drops, etc.
7. Early identification of cases suspected to be suffering from common eye diseases such as conjunctivitis, dry eyes, eye allergies, sty, trachoma, squint, etc.
8. Ensure access to free spectacles and motivating individuals to regularly wear spectacles, motivation for eye donation, counselling of identified patients for cataract surgery, compliance for glaucoma, etc. amongst the individuals visiting AB-HWCs.
9. Provide first aid of injured eye.
10. Compilation and validation of data reported by AB-HWCs as per guidance of MO.
11. Follow- up is a very important step in order to complete the cycle of comprehensive health care. Provide follow up care to patients who have undergone eye surgery/other eye procedures, as advised by the referral centre. Ensure that they receive complete care and, if on treatment, are complying with all the advice given to them. Long term follow- up will be necessary for certain cases.
12. Collaborate with the primary healthcare team, arrange for rehabilitation for those with long term and permanent blindness including vocational rehabilitation, re- integration into school, etc.
13. Stock management for eye related medicines and equipment.
14. Maintenance of registers and records related to eye health.

### **Ophthalmic Assistant (OA) at Vision Centres (VC):**

1. Work under the supervision of Medical Officer/Eye Specialist/Eye Doctor.
2. Screening and identification of eye diseases, distribution of spectacles, provide primary eye care including treatment for eye diseases, refer complex cases for surgery, organize eye screening camps, school eye health sessions and community health education sessions.

## Monitoring and Supervision

Monitoring and supervision are important to maintain service delivery and improving quality of services being provided. The data thus generated also allows decision makers to track progress and make changes in the service delivery mechanisms or the services themselves as per the needs of the population and priorities of decision makers. The indicators that will be used for the purpose of monitoring and supervision of AB-HWC-PHC/UPHC team are listed in the table below.

**Table 6: Indicators for monitoring and supervision**

S No	Indicator	Calculation
1.	Proportion of blind and Visually impaired identified	(Number of blind and Visually impaired identified / catchment population of AB-HWC) x 100
2.	Percentage of blind and Visually impaired referred	(Number of blind and Visually impaired referred/total number of individuals identified as being blind and Visually impaired) X 100
3.	% of cataract identified and referred	(Number of cases with cataract identified and referred/ total number of home visits) X 100
4.	% of Diabetic Retinopathy identified and referred	(Number of Out-Patient Department (OPD) cases with diabetic retinopathy identified and referred/total number of OPD) X 100
5.	% of eye injuries identified and referred	(Number of OPD cases with eye injuries identified and referred/ total number of OPD) X 100
6.	Number of cataract surgeries conducted in the catchment area	NA
7.	Number of refraction/ glasses prescribed at the OPD of the unit/centre	NA
8.	Number of spectacles distributed at the OPD of the unit/centre	NA

Monitoring and supervision can be done through multiple mechanisms:

- Supportive supervision:** Supportive supervision involves on-site observation with aim of helping improve the skills (capacity building) of the team members gradually over a period of time. Usually on-site correction of mistakes, if any are being made is done. This is an ongoing process which also helps in building interpersonal relationship among team members which helps team work. This can usually be done during routine field visits by the Medical Officer.
- Monthly meetings:** At the time of monthly meetings, the work and performance of team members can be discussed by the medical officer and appropriate direction may be given at the same time. This opportunity can also be used to organize a small training session for ASHA, AF, MPW/ANM, CHO, Staff Nurse or other staff to improve their skills.
- Meetings with other stakeholders:** Usually community members or community platforms/organizations provide useful feedback regarding the coverage and quality of services being delivered to the community. This feedback may be utilized to improve upon the planning, delivery of services as well as their monitoring and supervision.

Refer to Annexure-6 for Medicines and Diagnostics available at Community, Ayushman Bharat-Health and Wellness Centres- SHC/PHC/UPHC and Referral Centre. Refer to Annexure-7 for commonly used medicines for Eye Diseases and Annexure- 8 regarding list of equipment for Eye Care.

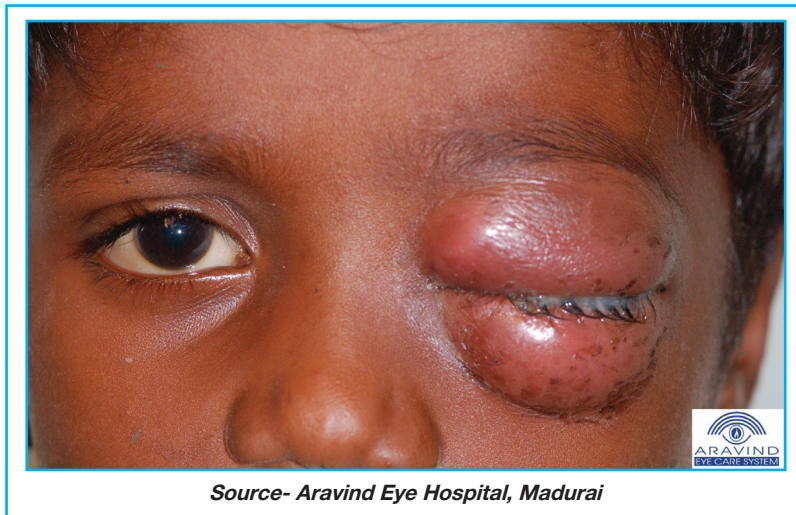# CHAPTER -16

## CLINICAL SCENARIOS

**Case Scenario 1:** 12-year-old boy, gives history of trauma with a rod to Left Eye (LE), 4 days ago. Has severe pain in and around the LE and fever for 2 days. On examination, LE vision is 6/9, LE has severe lid oedema, gross chemosis, extra ocular movements are restricted and pupil is normally reactive.

Questions:

1. What is the likely diagnosis?
2. What is your next plan of management at your centre?



Ans: Orbital Cellulitis.

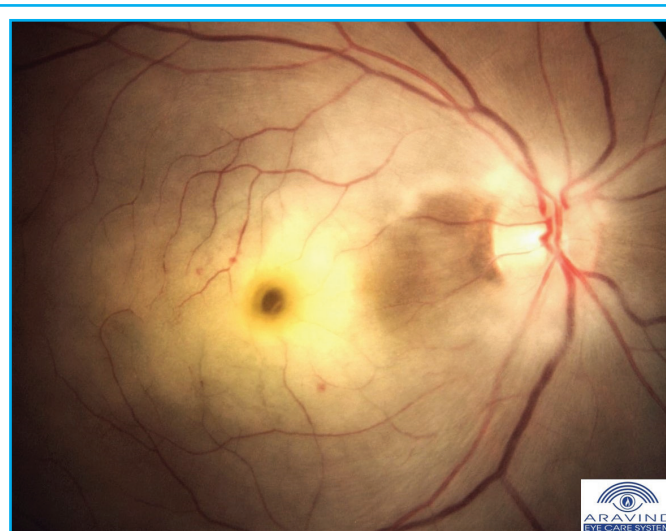
Plan of Management: Start systemic Antibiotic, Refer to Ophthalmologist.

**Case scenario 2:** 55-year-old male, has sudden loss vision of the Right Eye (RE) for the last 2 hours, no pain, no trauma. RE vision-Light perception with a definite RAPD.

Questions:

1. What is the likely diagnosis?
2. What is your next plan of management at your centre?





Source- Aravind Eye Hospital, Madurai

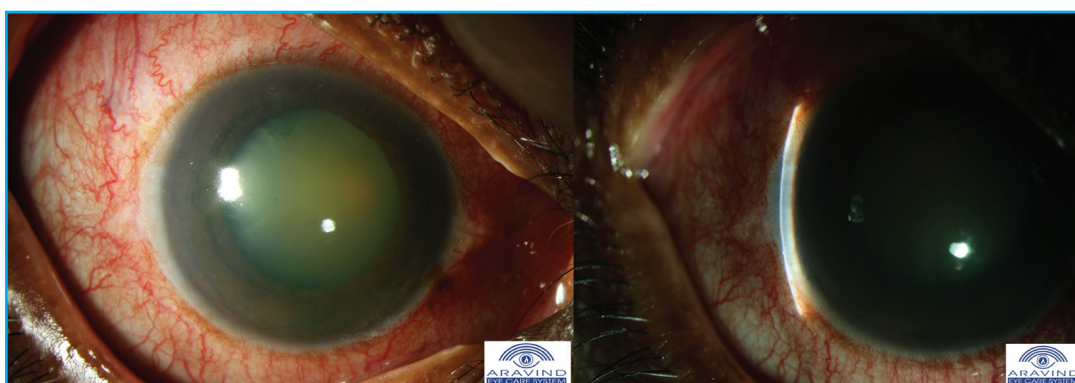
Ans: Central Retinal Artery Occlusion.

Plan of Management: Refer immediately to an Ophthalmologist. This is an ocular emergency.

**Case scenario 3: 50-year-old female, RE severe pain from last night and vomiting, no trauma. No previous surgeries/lasers. RE vision is 1/60, not improving. RE lid oedema, ciliary congestion, cornea hazy due to oedema, pupil can just be made out and appears to be 5 mm, fixed and vertically oval. The fundus cannot be seen. LE the cornea is clear, Anterior chamber appears shallow and lens has Immature Cataract.**

Questions:

1. What is the likely diagnosis?
2. What is your next plan of management at your centre?



Source- Aravind Eye Hospital, Madurai

Ans: Acute angle closure Glaucoma attack.

Plan of Management: May give Oral Glycerol or Oral Acetazolamide.

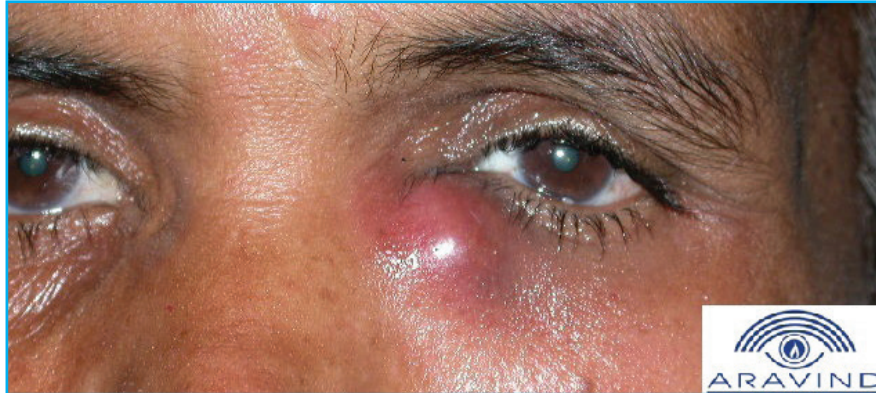Pilocarpine eye drops if available can be put in the Eye.

Refer immediately to an Ophthalmologist.

**Case scenario 4: 55 years female, says she was having watering from the Left eye for 3 months and for the last 3 days she has developed pain and swelling of the Left-side eyelids and redness in the area next to the nose. She has severe pain on touching the area around the nose. Left eye exam shows the lids are oedematous and lashes are matted, anterior segment is normal.**

Questions:

1. What is the likely diagnosis?
2. What is your next plan of management at your centre?



*Source- Aravind Eye Hospital, Madurai*

Ans. Acute Dacryocystitis.

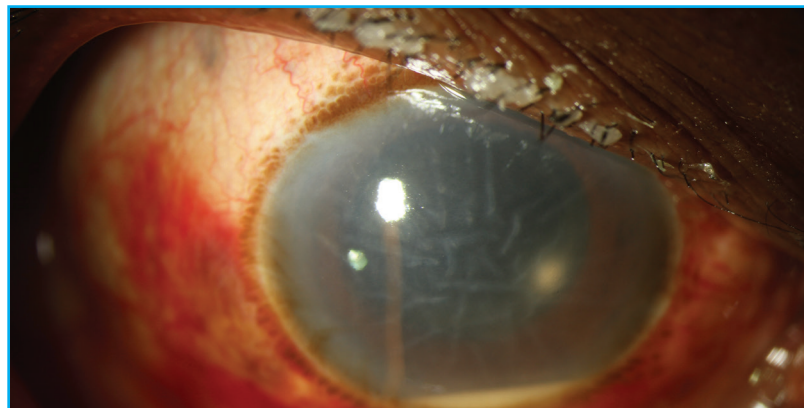
Plan of Management: Start oral Antibiotics and NSAIDs and Hot compresses.

To be referred to an Ophthalmologist.

**Case Scenario 5: 60-year-old diabetic male, underwent LE cataract surgery 15 days ago, complains of pain and defective vision in the LE for last 5 days. No trauma. RE vision 6/9, has Posterior chamber intraocular lenses. LE vision is 1/60, there is ciliary congestion and the cornea is very hazy, there is appears to be a 2 mm hypopyon. Fundus cannot be seen due to hazy media.**

Questions:

1. What is the likely diagnosis?
2. What is your next plan of management at your centre?



*Source- Aravind Eye Hospital, Madurai*



Ans: Post-Surgical Endophthalmitis.

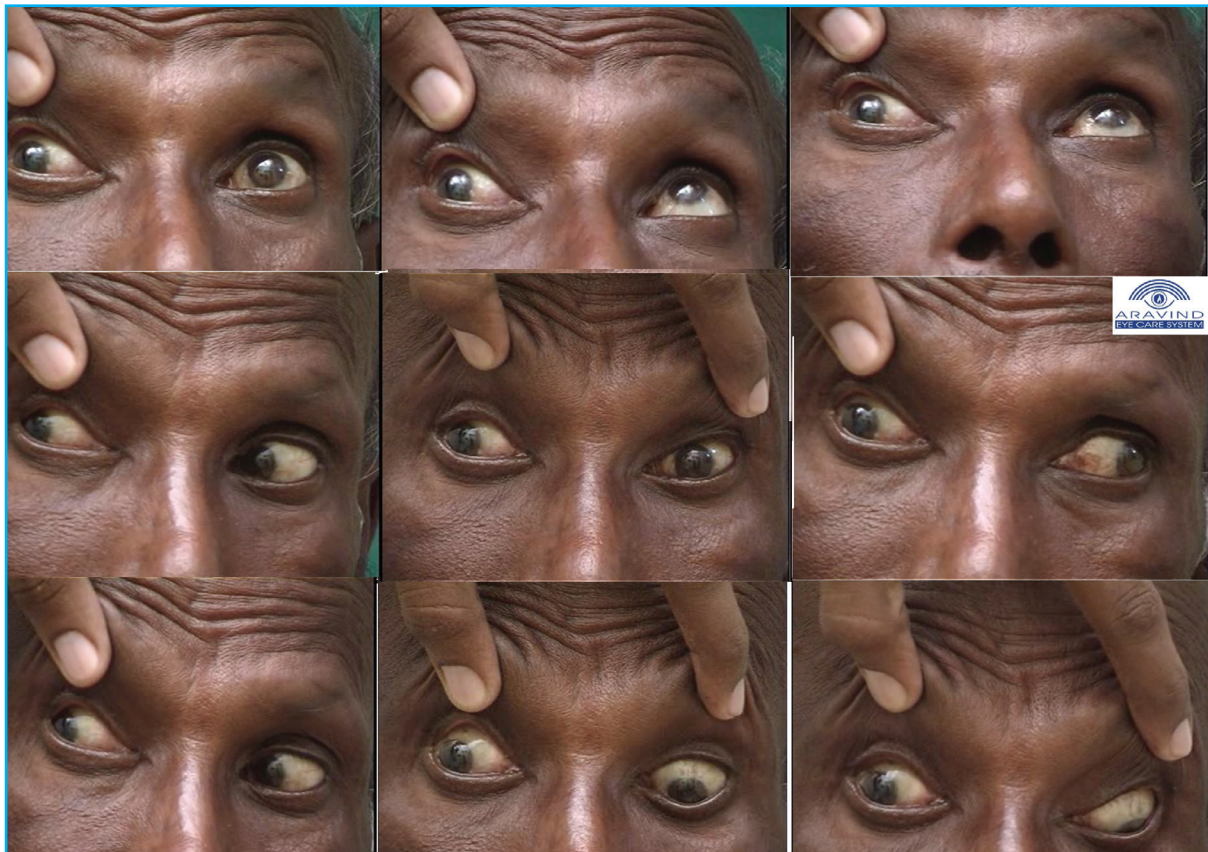Plan of Management: May start broad spectrum local Antibiotics and a Mydriatic Eye drop.

Refer immediately to the Eye Surgeon who had operated on the patient or in case operated in a far-off base camp, send patient to tertiary eye care hospital as he may need a Vitrectomy or an Intravitreal injection.

**Case scenario 6: 55-year-old male has headache for the last 1 month, and is not able to open the Right eye for the last 2 days. On examining, the RE vision is 6/12 anterior segment shows 6 mm, fixed pupil, not reacting to light, and the RE is directed down and out with limited adduction and elevation. With both eye open with the fingers, patient says he sees double images.**

Questions:

1. What is the likely diagnosis?
2. What is your next plan of management at your centre?
3. Why is this an Emergency?



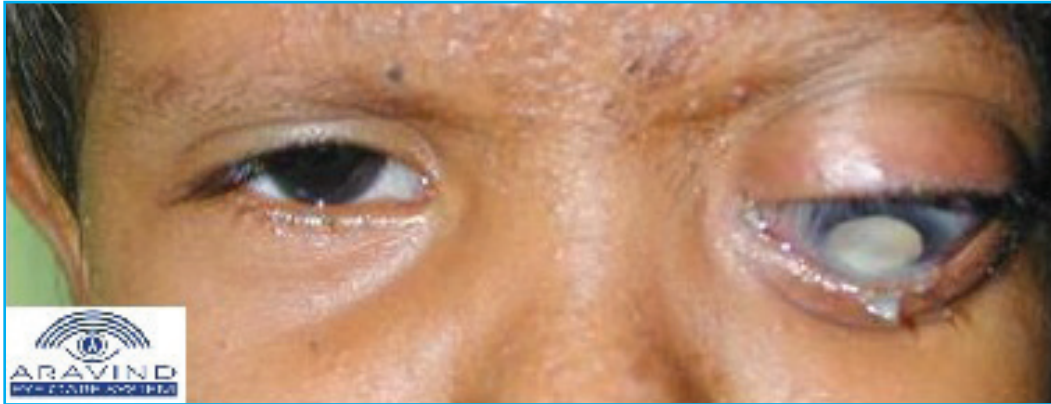*Source- Aravind Eye Hospital, Madurai*

Ans: Pupil involving Third nerve palsy.

Plan of Management: Immediate referral to Eye specialist at a tertiary care centre.

**Case scenario 7: 3-year-old child brought by the mother saying that the child is having white pupil reflex in LE for 10 days and has been crying continuously. On examining, The RE appears to be normal, the LE appears prominent and large and a white pupil reflex can be made out on torch light.**

Possible differential diagnosis-



*Source- Aravind Eye Hospital, Madurai*

Ans: Retinoblastoma.

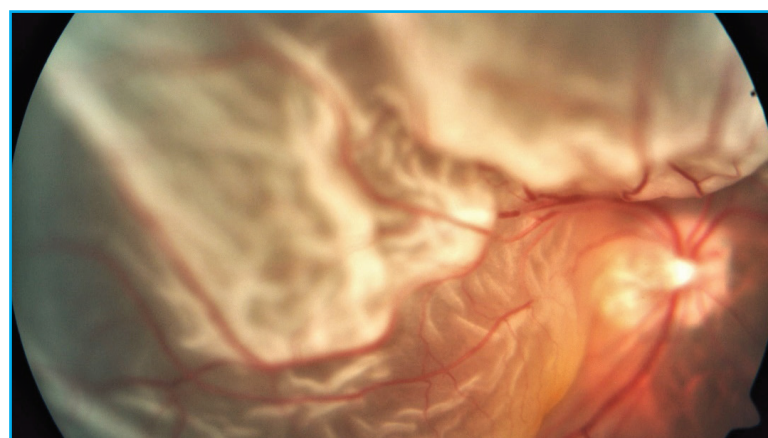
Plan of Management: this is a potentially Life and Sight threatening disease and should be referred to a hospital having Paediatric Ophthalmology set up.

Explain the poor visual prognosis to the parents and ask them to get other siblings screened for any such tumour in their eyes.

**Case scenario 8: 45-year-old male says he is seeing flashes of light in RE for 3 days when he moves his eye sided to side. Vision in both eyes is 4/60, improving to 6/9 with -9 Diopter sphere, -2 Diopter Cylinder 90 deg. Anterior segment of both eyes show deep anterior chamber but is otherwise normal. Undilated Posterior segment examination shows the disc and macula to be normal.**

Questions:

1. What is the likely diagnosis?
2. What is your next plan of management at your centre?



*Source- Aravind Eye Hospital, Madurai*

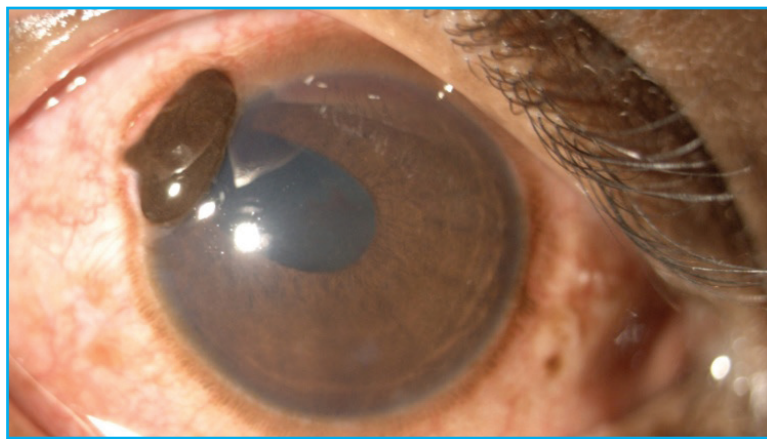
Ans: Retinal Detachment.

Plan of Management: Refer immediately to a tertiary care Eye Hospital. Early Treatment can save some sight.

**Case scenario 9: 24-year-old male, suffered trauma with a stick to RE 3 hours ago while working in the fields. He says he has lost vision after the injury and has severe pain in the RE. On examining, his vision is perception of light in RE, 6/6 in LE. RE has a large central corneal tear with black colour tissue attached to it. The anterior chamber is very shallow, the lens and pupil cannot be seen due to hyphaema in the anterior chamber.**

Questions:

1. What is the likely diagnosis?
2. What is your next plan of management at your center?



*Source- Aravind Eye Hospital, Madurai*

Ans: Corneal Tear with iris prolapse/ Open globe injury.

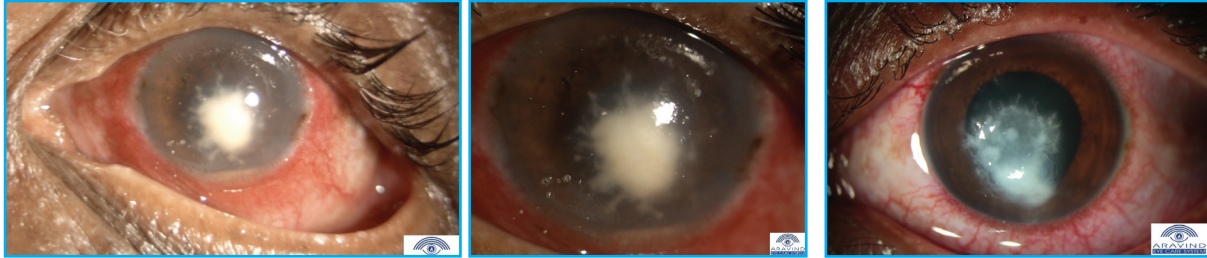
Plan of Management: Instil antibiotic drops in the eye, Pad and patch the eye and refer to an Ophthalmologist.



**Case scenario 10: 35-year-old male says he has been having pain, redness and white spot in one eye for 5 days. History of injury with a tree twig while cutting wood. Cornea is cloudy with a dense opacity with fuzzy margins and a hypopyon.**

Questions:

1. What is the likely diagnosis?
2. What are the likely complications if not treated?



*Source- Aravind Eye Hospital, Madurai*

Ans: Fungal Corneal Ulcer.

Plan of Management: Start patient on Mydriatic drops and any available anti-fungal drops. May give systemic NSAIDs.

Refer to an ophthalmologist immediately as these ulcers are very chronic and difficult to treat.

# ANNEXURES

## Annexure 1- Removal of superficial foreign bodies in the eye

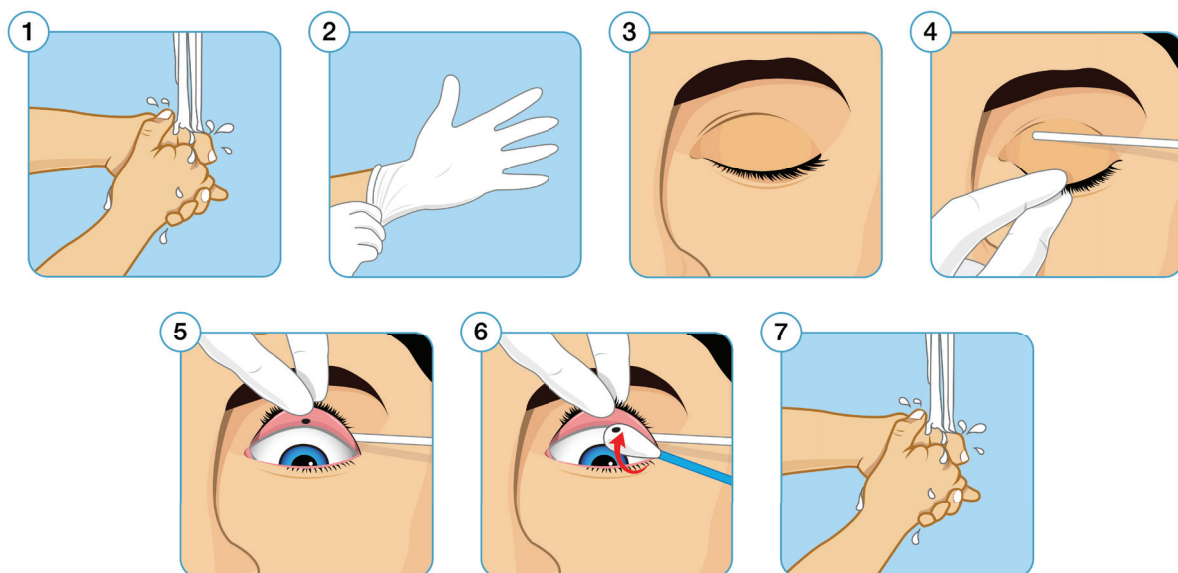
### Management of foreign body in the eye

Being exposed to the external world, foreign bodies such as dust, sand, small stones, etc. commonly get lodged in the eye. Whereas, in most cases the foreign bodies are superficial, favouring easy removal by you, in rare cases these articles may get lodged deep in the eye, needing management by Eye specialist/Eye doctor.

#### Steps for removal of superficial foreign bodies:

- While you hold her/his eye open, have her/him look to the left, right, up and down (this step should be done only once).
- This will make the eye produce more tears and the dirt often comes out by itself.
- Or you can try to remove the bit of dirt or sand by flooding the eye with clean water or by using the corner of a clean cloth or some moist cotton.

If the particle of dirt is under the upper lid, look for it by turning the lid up over a thin stick. The person should look down while you do this. This is shown diagrammatically as follows:



If you cannot get the particle out easily, use an antibiotic eye ointment (as prescribed). Cover the eye with an eye pad, and refer the patient to Eye Specialist/Eye Doctor for further care.


## Annexure 2- Eye Screening Tool to be used at Various Levels

### 2.1 Vision Chart at Community Level (Snellen Vision Chart-6/18 E-chart)

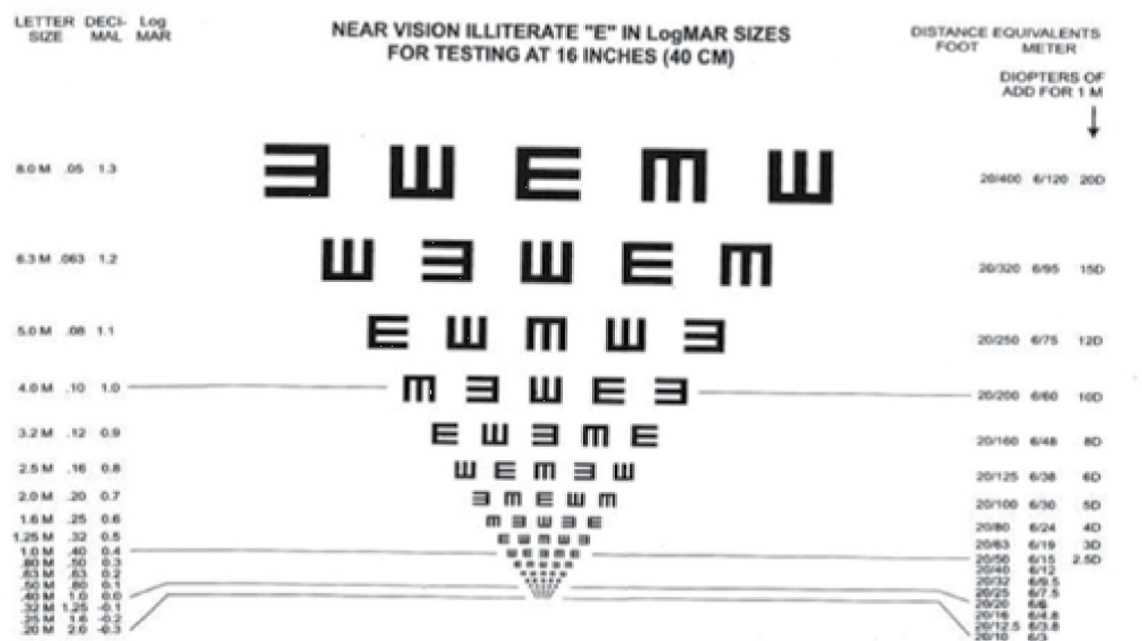


### 2.2 Ayushman Bharat- Health and Wellness Centre and Referral Centre/Vision Centre

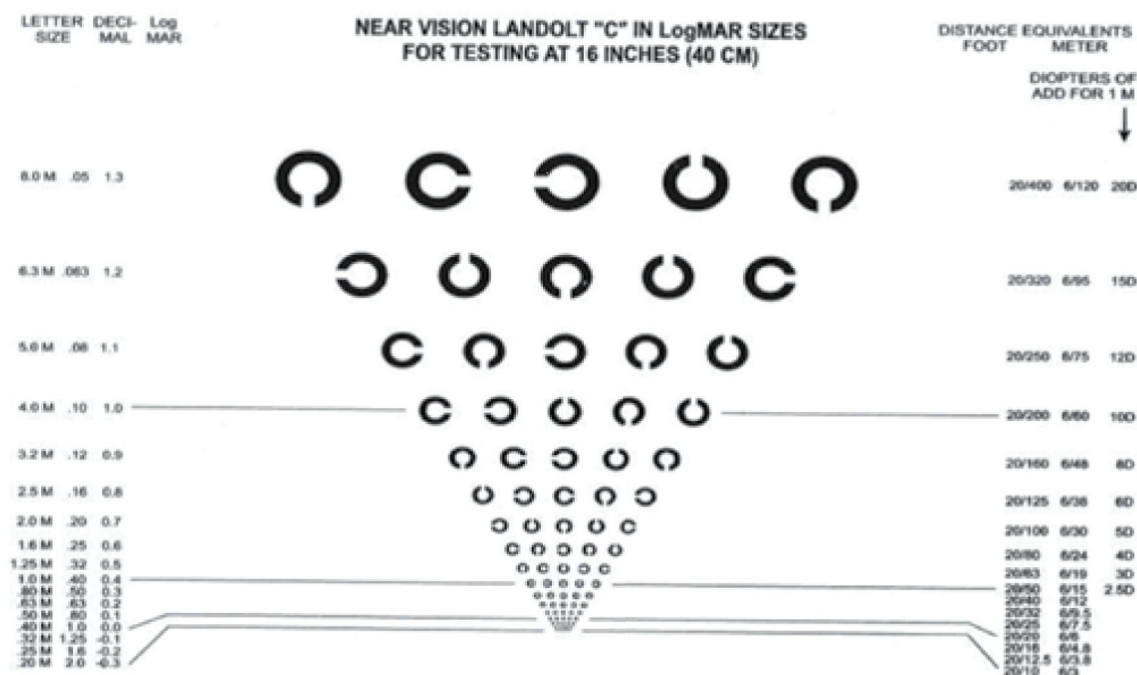
#### 1. Snellen's Chart



## 2. Near vision chart



#108004

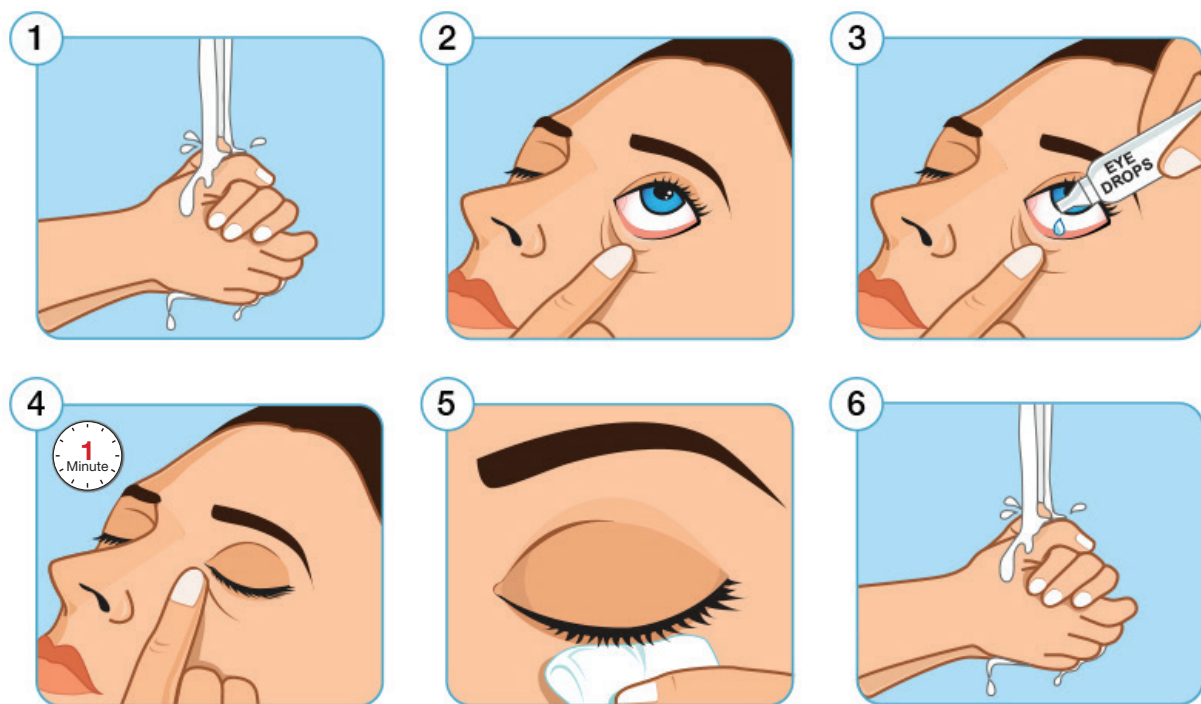


### **Annexure 3- How to apply Eye Drops correctly**

**You may counsel the individual or families for following the correct steps given below while applying eye drops.**

1. Check for the expiry date of the eye drops and make sure that you have the correct medication.
2. Wash your hands with soap and clean water before using eye drops, to prevent dirt or germs from getting into your eye.
3. If you also use contact lenses, it is advisable to put your eye drops when you are not wearing contact lenses. Put them back into your eye at least 15 minutes after using eye drops.
4. Do not put the eye drops directly into the eye. Tilt your head back and gently pull your lower eyelid down (this forms a pocket) with your finger. Look up.
5. Hold the bottle close to your eye. Do not let the bottle tip touch your eye, eyelid, eye lashes or skin-If it does, the eye drop bottle will need to be discarded. Eye drops should be put into the eye from a distance.
6. Put only one drop at a time in the pocket made. Squeeze the eye drops into your lower eyelid, without touching your eye.
7. Let go of your eyelid and close your eyes. You should not keep blinking your eyes after putting the eye drop. Individual should not squeeze the eyes tightly as the eye drops will come out.
8. To keep the drop for the maximum time in the eye, put some pressure on your nose with your finger near the corner of the eye. It is normal if you, sometimes, feel the taste of the eye drop in your throat.
9. Keep your eye closed for about one minute after putting the eye drop.
10. Now, put the eye drop in the other eye if suggested by the doctor, by following the steps as given above.
11. If you need to put other eye drops as well, then there must be a gap of 5-10 minutes between each eye drop.
12. If you need to apply an eye ointment also then make sure to use it after putting all the eye drops.
13. Wash your hands with soap and clean water after using eye drops.
14. Try using eye drops while sitting and while lying down, to see whether it is easier for you to apply eye drops in either position.
15. Once the eye drop bottle is open, it must be used within one month. Discard the eye drop bottle after one month of opening (even if it is not empty).
16. Do not use eye drops prescribed to another person/family member.
17. Be careful in using the eye drops. Do not use ear drops into the eyes.
18. You must put the drops at the right time interval as suggested by your medical doctor. If you put the drops every day, you should put it at the same fixed time every day as far as possible.



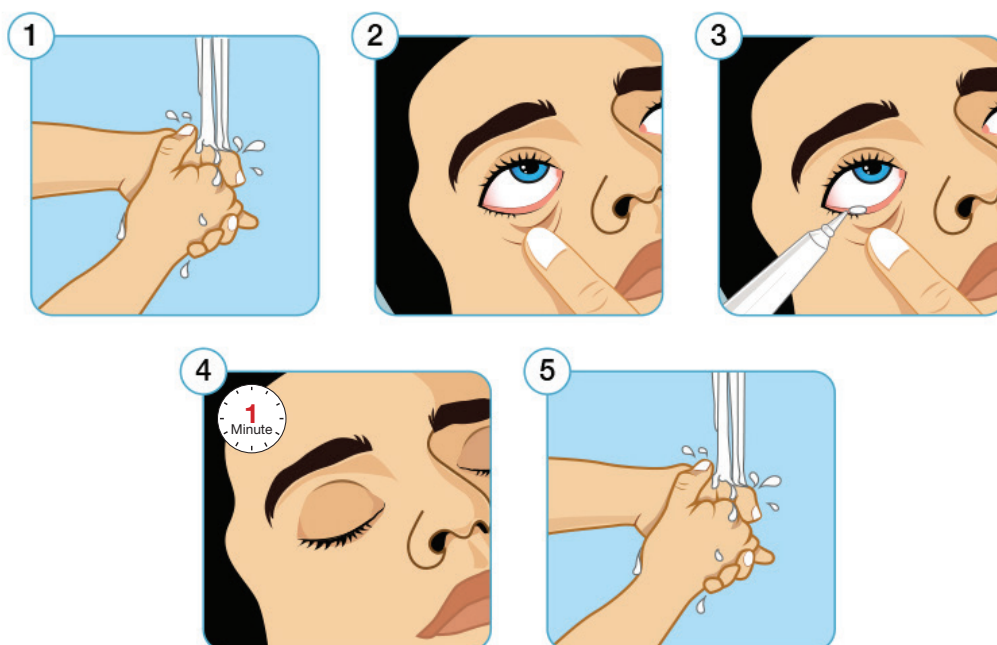


*How to apply Eye Drops correctly*

#### Annexure 4- How to apply Eye Ointment correctly

You may counsel the individual or families for following the correct steps given below while applying eye ointment.

1. Check for the expiry date of the eye ointment and make sure that you have the correct medication.
2. Wash your hands with soap and clean water before using the eye ointment, to prevent dirt or germs from getting into your eye.
3. Do not put the eye ointment directly into the eye. Tilt your head back and gently pull your lower eyelid down (this forms a pocket) with your finger. Look up.
4. Hold the eye ointment close to your eye. Do not let the tip of the ointment tube touch any part of your eye (eyelid or eye lashes). If it does, the ointment tube will have to be discarded.
5. The quantity of the eye ointment should be just enough (like size of rice/wheat grain). Do **NOT** apply the eye ointment as applying kajal.
6. Let go of your eyelid and close your eyes. You should not keep blinking your eyes after putting the eye ointment. Individual should not squeeze the eyes tightly as the eye ointment will come out. Wipe away any surplus ointment which may come out.
7. Keep your eye closed for about one minute after putting the eye ointment in one eye. Then, put the ointment in the other eye if suggested by the doctor by following the above steps.
8. Wash your hands with soap and clean water after using the eye ointment.
9. The eye ointment should be applied only after putting all the eye drops.
10. Explain to the individual that their vision will be blurry (not clear) for a few minutes.
11. Close the cap of the ointment tube. Once the eye ointment is open, it must be used only for one month. Discard the eye ointment tube after one month of opening (even if it is not empty).
12. Do not use eye ointment given to another person/family member.
13. You must put the eye ointment at the right time interval as suggested by your medical doctor.



*How to apply Eye Ointment correctly*

## Annexure 5- Community Based Assessment Checklist (CBAC)

General Information		Date : DD/MM/YYYY
Name of ASHA:	Village/Ward:	
Name of MPW/ANM:	Sub Centre:	
	PHC/UPHC:	
Personal Details		
Name:	Any Identifier (Aadhar Card/ any other UID – Voter ID etc.):	
Age:	State Health Insurance Schemes: Yes/No If yes, specify:	
Sex:	Telephone No. (self/family member /other - specify details):	
Address:		
Does this person have any of the following: visible defect /known disability/Bed ridden/ require support for Activities of Daily Living	If yes, Please specify	

Part A: Risk Assessment				
Question	Range		Circle Any	Write Score
1. What is your age? (in complete years)	0 – 29 years		0	
	30 – 39 years		1	
	40 – 49 years		2	
	50 – 59 years		3	
	≥ 60 years		4	
2. Do you smoke or consume smokeless products such as gutka or khaini?	Never		0	
	Used to consume in the past/ Sometimes now		1	
	Daily		2	
3. Do you consume alcohol daily	No		0	
	Yes		1	
4. Measurement of waist (in cm)	Female	Male		
	80 cm or less	90 cm or less		
	81-90 cm	91-100 cm		
	More than 90 cm	More than 100 cm		
5. Do you undertake any physical activities for minimum of 150 minutes in a week? (Daily minimum 30 minutes per day – Five days a week)	At least 150 minutes in a week		0	
	Less than 150 minutes in a week		1	
6. Do you have a family history (any one of your parents or siblings) of high blood pressure, diabetes and heart disease?	No		0	
	Yes		2	

Part A: Risk Assessment				
Question	Range		Circle Any	Write Score
Total Score				
Every individual needs to be screened irrespective of their scores.				
A score above 4 indicates that the person may be at higher risk of NCDs and needs to be prioritized for attending the weekly screening day				

Part B: Early Detection: Ask if Patient has any of these Symptoms			
B1: Women and Men	Y/N		Y/N
Shortness of breath (difficulty in breathing)		History of fits	
Coughing more than 2 weeks*		Difficulty in opening mouth	
Blood in sputum*		Any ulcers in mouth that has not healed in two weeks	
Fever for > 2 weeks*		Any growth in mouth that has not healed in two weeks	
Loss of weight*		Any white or red patch in mouth that has not healed in two weeks	
Night Sweats*		Pain while chewing	
Are you currently taking anti-TB drugs**		Any change in the tone of your voice	
Anyone in family currently suffering from TB**		Any hypopigmented patch(es) or discolored lesion(s) with loss of sensation	
History of TB *		Any thickened skin	
Recurrent ulceration on palm or sole		Any nodules on skin	
Recurrent tingling on palm(s) or sole(s)		Recurrent numbness on palm(s) or sole(s)	
Cloudy or blurred vision		Clawing of fingers in hands and/or feet	
Difficulty in reading		Tingling and numbness in hands and/or feet	
Pain in eyes lasting for more than a week		Inability to close eyelid	
Redness in eyes lasting for more than a week		Difficulty in holding objects with hands/ fingers	
Difficulty in hearing		Weakness in feet that causes difficulty in walking	
B2: Women only	Y/N		Y/N
Lump in the breast		Bleeding after menopause	
Blood stained discharge from the nipple		Bleeding after intercourse	
Change in shape and size of breast		Foul smelling vaginal discharge	
Bleeding between periods			
B3: Elderly Specific (60 years and above)	Y/N		Y/N
Feeling unsteady while standing or walking		Needing help from others to perform everyday activities such as eating, getting dressed, grooming, bathing, walking, or using the toilet	
Suffering from any physical disability that restricts movement		Forgetting names of your near ones or your own home address	
In case of individual answers Yes to any one of the above-mentioned symptoms, refer the patient immediately to the nearest facility where a Medical Officer is available			
*If the response is Yes- action suggested: Sputum sample collection and transport to nearest TB testing center			
** If the answer is yes, tracing of all family members to be done by ANM/MPW			

<b>Part C: Risk factors for COPD</b>
<b>Circle all that Apply</b>
Type of Fuel used for cooking – Firewood / Crop Residue / Cow dung cake / Coal / Kerosene / LPG
Occupational exposure – Crop residue burning/burning of garbage – leaves/working in industries with smoke, gas and dust exposure such as brick kilns and glass factories etc.

<b>Part D: PHQ 2</b>					
Over the last 2 weeks, how often have you been bothered by the following problems?		Not at all	Several days	More than half the days	Nearly every day
1.	Little interest or pleasure in doing things?	0	+1	+2	+3
2.	Feeling down, depressed or hopeless?	0	+1	+2	+3
Total Score					
Anyone with total score greater than 3 should be referred to CHO/ MO (PHC/UPHC)					



## Annexure 6 - Medicines and Diagnostics

The following medicines and consumables should be available at Community, Ayushman Bharat- Health and Wellness Centres - SHC/PHC/UPHC and Referral Centre.

Community Level	Ayushman Bharat-Health & Wellness centre- Sub Health Centre
Vitamin A prophylaxis	<b>Essential</b> <ul style="list-style-type: none"> <li>• Eye drops Methyl cellulose*</li> <li>• Eye drops Sodium Cromoglycate 2%</li> <li>• Facilities for pad and patching of the eye</li> </ul> <b>Desirable:</b> (to be dispensed only on prescription of a registered Medical Practitioner) <ul style="list-style-type: none"> <li>• Eye drops Ciprofloxacin 0.3%</li> <li>• Eye ointment Ciprofloxacin 0.3%</li> <li>• Eye drops Tropicamide 1%</li> </ul>
Ayushman Bharat-Health & Wellness centre-PHC/UPHC	Referral Centre/Vision Centre
<ul style="list-style-type: none"> <li>• Eye drops Methyl cellulose*</li> <li>• Eye drops Sodium cromoglycate 2%</li> <li>• Eye drops Lignocaine 4%</li> <li>• Eye drops Ciprofloxacin 0.3%**</li> <li>• Eye ointment Ciprofloxacin 0.3%**</li> <li>• Eye drops Tropicamide 1%**</li> <li>• All medicines as per Essential Medicine List</li> </ul>	<ul style="list-style-type: none"> <li>• Tab Acetazolamide 250 mg</li> <li>• Eye drop Lignocaine 4%</li> <li>• Eye drop Tropicamide 1%</li> <li>• Eye drop Pilocarpine 2% and 4%</li> <li>• Eye drop Cyclopentolate 1%</li> </ul>
*Do not use / store eye drops containing steroids. **To be dispensed only on prescription of a registered Medical Practitioner.	

Source: Adapted from Operational Guidelines for Eye Care at Health and Wellness Centres, GOI, 2020.

## Annexure 7- Commonly used medicines for Eye Diseases

Uses	Side effects	Dosage
<b>Methyl cellulose eye drops:</b>		
It is an eye lubricant which keeps the eye moist, helps to protect the eye from injury and infection, and decreases the symptoms of dry eyes such as burning, itching, and feeling as if something is in the eye.	Vision may be temporarily blurred when this product is first used. Also, minor burning/stinging/irritation may temporarily occur. Rare but serious side effect is allergic reaction including rash, itching/swelling (especially of the face/ tongue/ throat), severe dizziness, trouble breathing.	1-2 drops in the affected eye, 3-4 times a day (or as prescribed by the Medical Doctor). Re-evaluate/ refer after 3 days, if no relief in symptoms.
<b>Sodium Cromoglycate 2% eye drops:</b>		
It is used in the treatment of acute, seasonal and perennial allergic conjunctivitis.	Transient stinging and burning on instillation. Rarely, hypersensitivity.	1-2 drops into each eye, up to 4 times a day (or as prescribed by the Medical Doctor).
<b>To be dispensed only on prescription of a registered Medical Practitioner</b>		
<b>Ciprofloxacin 0.3% eye drops/eye ointment:</b>		
This medication is used to treat bacterial eye infections. It will not work for other types of eye infections. Ciprofloxacin belongs to a class of drugs called quinolone antibiotics and works by stopping the growth of bacteria. Unnecessary use or overuse of any antibiotic can lead to its decreased effectiveness.	This medication may cause temporary stinging or burning sensation in patient's eyes. Some other less common side effects include itching, redness, tearing, eyelid crusting, foreign body sensation in the eye, blurred vision, a bad taste in mouth, or sensitivity to light. Rarely it may cause allergic reactions.	Depending on the severity of the condition the dosage may change slightly. For conjunctivitis, the usual dose is around 1-2 drops in the affected eye, every 4-6 hours and eye ointment in the eye (or as prescribed by the Medical Doctor).
<b>Tropicamide 1% eye drops:</b>		
This medication is used to widen (dilate) the pupil of the eye in preparation for certain eye examinations. It belongs to a class of drugs known as anticholinergics. Tropicamide works by relaxing certain eye muscles.	Transient stinging and burning on instillation. Rarely- hypersensitivity.	1-2 drops, 15-20 mins before the scheduled eye examination (or as prescribed by the Medical Doctor). May be repeated once if needed.

## Annexure 8- List of Equipment for Eye Care

The following equipment should be available at Community, Ayushman Bharat- Health & Wellness Centre and Referral Centre:

Community Level	Ayushman Bharat- Health and Wellness Centre	Referral Centre/ Vision Centre
<p><b>ASHA kit:</b> Vision Screening card for 6/18 vision, Measuring tape (6 meter), Recording format, Reading module, Referral cards.</p> <p><b>School Teacher kit:</b> Vision Screening card of 6/9 vision, Measuring tape (6 meter), Recording format, Reading module, Referral cards.</p>	<p><b>Instruments:</b></p> <ul style="list-style-type: none"> <li>Covered stainless steel tray with sterile cottons/swabs/gloves</li> </ul> <p><b>Equipment:</b></p> <ul style="list-style-type: none"> <li>Illuminated/Non-Illuminated Vision chart (near &amp; distant)</li> <li>Torch (with batteries)</li> <li>Data entry - mechanism (e.g. Registers/tablets/PCs)</li> <li>IEC materials (Flipcharts, Posters &amp; Brochures for common eye conditions)</li> <li>Access to electronic learning material; can be developed by reviewing various existing models from the institution/ Non-Governmental Organization (NGOs)</li> </ul>	<p><b>Essential Equipment:</b></p> <ul style="list-style-type: none"> <li>Trial set</li> <li>Trial frame (adult and child)</li> <li>Tonometer (Schiotz)</li> <li>Direct Ophthalmoscope</li> <li>Illuminated Vision Testing Drum</li> <li>Plane mirror for retinoscopy</li> <li>Streak Retinoscope</li> <li>Snellen &amp; Near Vision Charts</li> <li>Binomag/magnifying loupe</li> <li>Torch (with batteries)</li> <li>Lid speculum</li> <li>Furnishing &amp; fixtures</li> <li>Slit lamp (optional)</li> <li>Epilation forceps</li> <li>Foreign body spud and needle</li> </ul> <p><b>Desirable Equipment's:</b></p> <ul style="list-style-type: none"> <li>Non-mydiatic fundus camera</li> <li>Non-contact tonometer</li> <li>Auto refraction meter</li> </ul>

Source: Adapted from Operational guidelines for Eye Care at Health and Wellness Centres, GOI, 2020.

## List of Contributors

Dr. Praveen Vashist	Officer In-charge, Community Ophthalmology, Dr. R. P. Centre for Ophthalmic Sciences, All India Institute of Medical Sciences (AIIMS), New Delhi
Dr. Promila Gupta	Principal Consultant, National Programme for Control of Blindness and Visual Impairment (NPCB&VI), DGHS, Ministry of Health & Family Welfare (MoHFW)
Dr. Sumit Malhotra	Additional Professor, Centre for Community Medicine, All India Institute of Medical Sciences (AIIMS), New Delhi
Dr. Pallavi Shukla	Assistant Professor, Preventive Oncology, Dr. BR Ambedkar Institute Rotary Cancer Hospital, All India Institute of Medical Sciences (AIIMS), New Delhi
Dr. Hariom Kumar Solanki	Assistant Professor (Community Medicine), Government Institute of Medical Sciences, Greater Noida, Uttar Pradesh
Dr. Shafi Ahmad	Scientist, Centre for Community Medicine, All India Institute of Medical Sciences (AIIMS), New Delhi
Dr. Aman Dua	Scientist, Centre for Community Medicine, All India Institute of Medical Sciences (AIIMS), New Delhi
Dr. Sankalp Singh Sharma	Medical Consultant, Department of Cornea and Refractive Surgery, Aravind Eye Hospital, Madurai, Tamil Nadu
Dr. Meghana Tanwar	Medical Consultant, Department of Orbit and Oculoplasty, Aravind Eye Hospital, Madurai, Tamil Nadu
Maj Gen (Prof) Atul Kotwal	Executive Director, National Health Systems Resource Centre (NHSRC)
Dr. M A Balasubramanya	Advisor - Community Processes and Comprehensive Primary Health Care, National Health Systems Resource Centre (NHSRC)
Dr. Neha Dumka	Lead Consultant, Knowledge Management Division, National Health Systems Resource Centre (NHSRC)
Dr. Suman	Senior Consultant, Community Processes and Comprehensive Primary Health Care, National Health Systems Resource Centre (NHSRC)
Dr. Devajit Bora	Senior Consultant, Community Processes and Comprehensive Primary Health Care, Regional Resource Centre for NE States
Dr. Shalini Singh	Former- Senior Consultant, Community Processes and Comprehensive Primary Health Care, National Health Systems Resource Centre (NHSRC)
Dr. Rupsa Banerjee	Former- Senior Consultant, Community Processes and Comprehensive Primary Health Care, National Health Systems Resource Centre (NHSRC)
Ms. Ima Chopra	Consultant, Community Processes and Comprehensive Primary Health Care, National Health Systems Resource Centre (NHSRC)
Ms. Pumani Kalita	Consultant, Community Processes and Comprehensive Primary Health Care, Regional Resource Centre for NE States
Dr. Praveen Davuluri	Former- Consultant, Community Processes and Comprehensive Primary Health Care, National Health Systems Resource Centre (NHSRC)
Dr. Maya Mascarenhas	External Consultant, National Health Systems Resource Centre (NHSRC)
Dr. Amit Dhage	Former- External Consultant, Community Processes and Comprehensive Primary Health Care, National Health Systems Resource Centre (NHSRC)

## NOTES:

[illegible]



[illegible]

## NOTES:

[illegible]

### **Namaste!**

You are a valuable member of the Ayushman Bharat – Health and Wellness Centre (AB-HWC) team committed to delivering quality comprehensive primary healthcare services to the people of the country.

To reach out to community members about the services at AB- HWCs, do connect to the following social media handles-



<https://instagram.com/ayushmanhwcs>



<https://twitter.com/AyushmanHWCs>



<https://www.facebook.com/AyushmanHWCs>



[https://www.youtube.com/c/NHSRC\\_MoHFW](https://www.youtube.com/c/NHSRC_MoHFW)



National Health Systems Resource Centre