



Introduction To Eye Care & Overview Of Anatomy Of Human Eye For CHO/SN

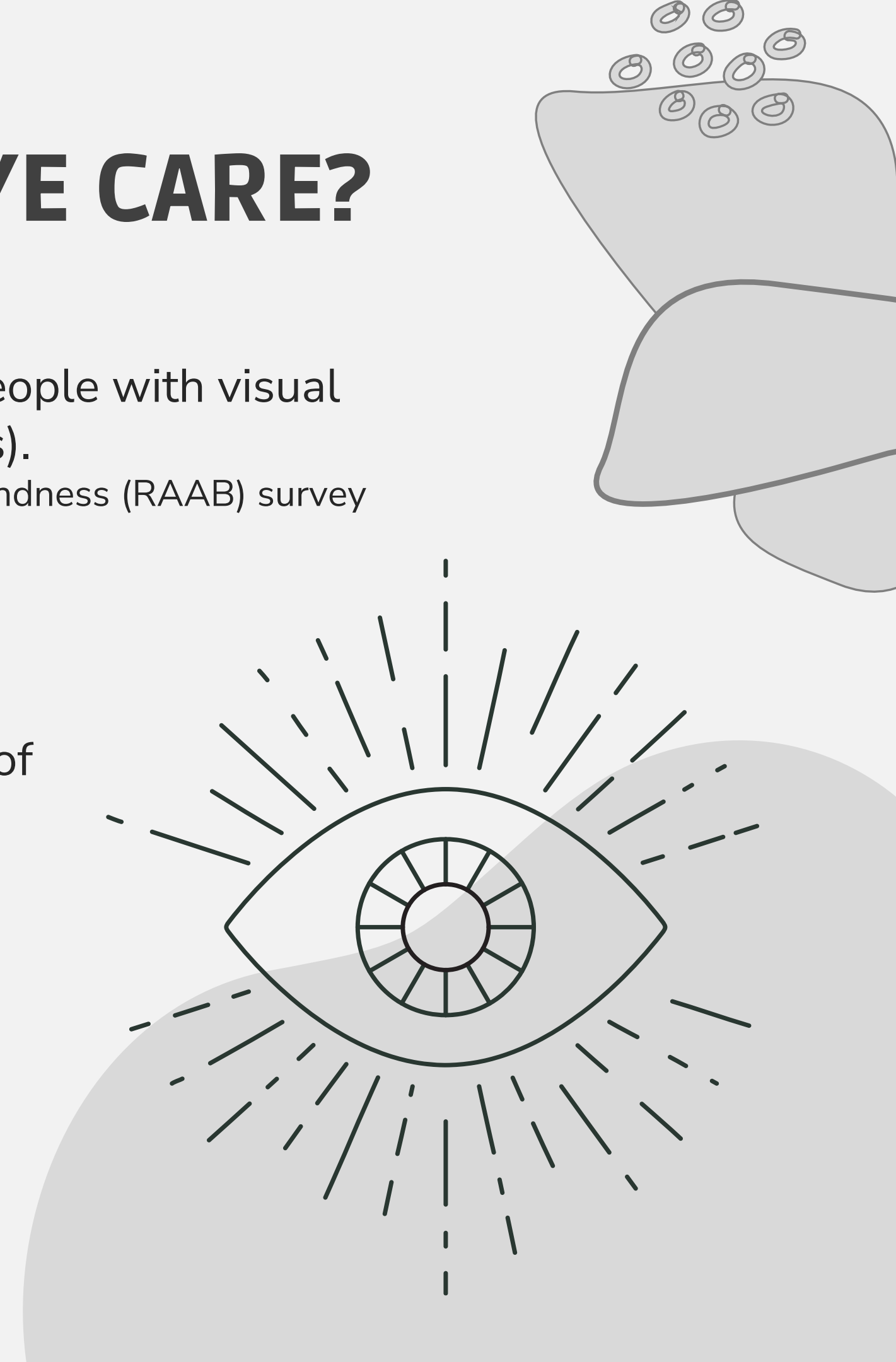




WHY IS THERE A NEED FOR EYE CARE?

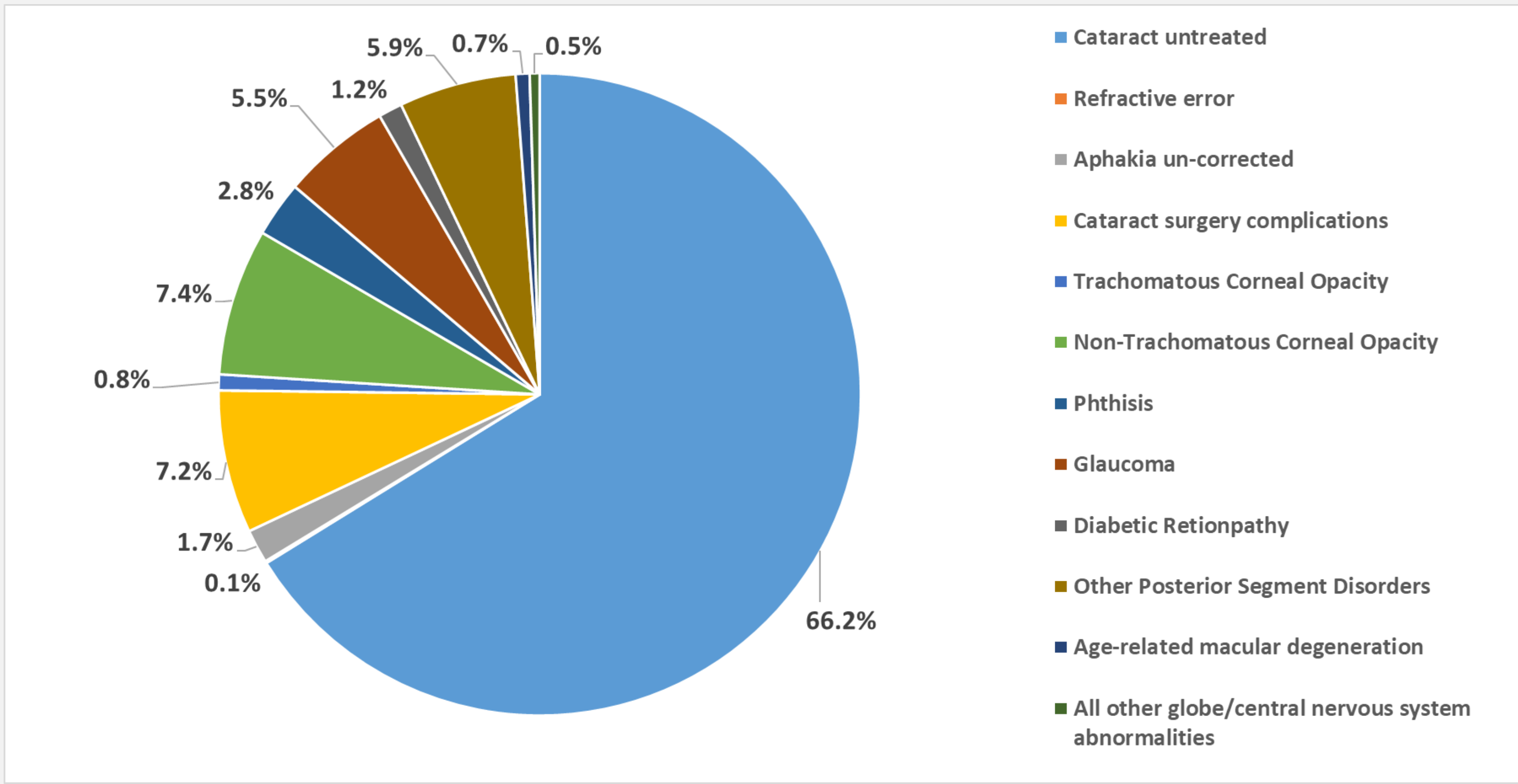
India has around 4.9 million blind people and 32.9 million people with visual impairment (presuming the population of India as 136 crores).
(Source-National Blindness Survey- The Rapid Assessment of Avoidable Blindness (RAAB) survey India- 2015-2019).

Refractive Error and cataracts are the most common causes of visual impairment in the country.





WHAT ARE THE PROBLEMS WITH THE EYE?



Source: Causes of blindness in 2019 in population aged ≥ 50 years, National Blindness & Visual Impairment Survey India, 2015-2019-A Summary Report



AYUSHMAN BHARAT- HEALTH AND WELLNESS CENTRES (AB-HWC)

- Care for Common Ophthalmic problems at AB-HWCs as part of Comprehensive Primary Health Care;
- Most cases with Eye problems are to be referred to the nearest AB-HWCs- both rural & urban areas;
- High-risk cases required to be referred to:
 - Ophthalmic Assistant (OA) at Vision Centres (as available);
 - Eye Specialist/Eye Doctor at the CHC/SDH/DH or other higher health facilities for complete diagnosis & treatment;

- **Rural areas:**

Community Health Officer (CHO) is heading the team at AB-HWC- Sub Health Centres (AB-HWC-SHC);

- CHO is responsible for referring cases to Medical Officer (MBBS) heading the AB-HWC-Primary Health Centre (AB-HWC-PHC);
- In some cases, CHO might refer cases to higher health facilities (all referrals undertaken will be in consultation with MO);

- **Urban areas:**





AYUSHMAN BHARAT- HEALTH AND WELLNESS CENTRES (AB-HWC)

Community Health Officer (CHO) is heading the team at AB-HWC- Sub Health Centres (AB-HWC-SHC);

- CHO is responsible for referring cases to Medical Officer (MBBS) heading the AB-HWC-Primary Health Centre (AB-HWC-PHC);
- In some cases, CHO might refer cases to higher health facilities (all referrals undertaken will be in consultation with MO);

- **Urban areas:**

Medical Officer (MBBS) heading the AB-HWC- Urban Primary Health Centre (AB-HWC-UPHC) is responsible for

all referrals;

- The Staff Nurse will assist MO in making arrangements for referrals

MO will support ASHA/ASHA Facilitators (AFs)/Multipurpose Worker/Auxiliary Nurse Midwife (MPW/ANM)/CHO/Staff Nurse in undertaking their tasks



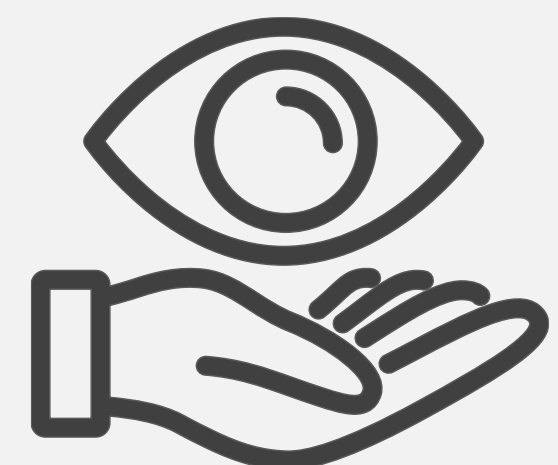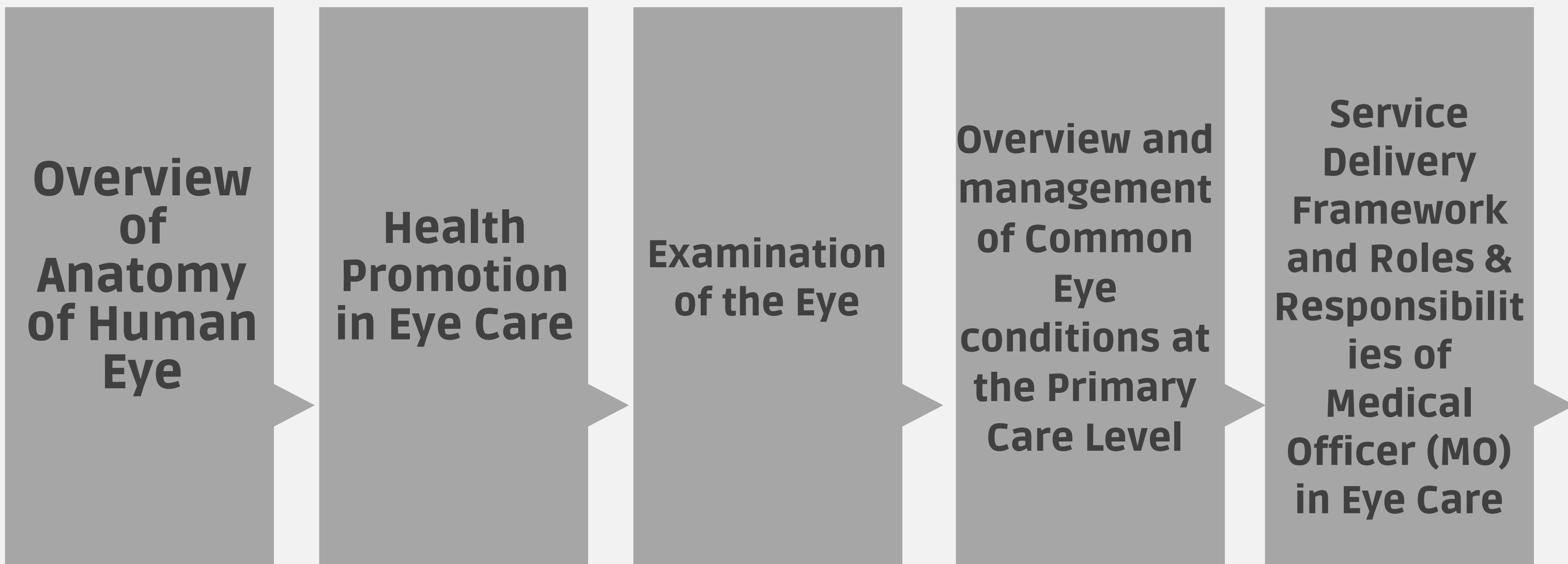


- India launched the National Programme for Control of Blindness (NPCB) in 1976
 - with the goal of reducing the prevalence of blindness to 0.3% by 2020
- Renamed as National Programme for Control of Blindness and Visual Impairment (NPCB&VI) in 2017
 - Apart from cataract surgeries, now the focus of the program is on the treatment and management of other eye diseases like- glaucoma, diabetic retinopathy, Vitreoretinal diseases, corneal blindness, low vision, and childhood blindness.
- The Programme is now geared to take care of all categories of visual impairment
- **Vision 2020: The Right to Sight**
 - 1999, launched by WHO to eliminate avoidable blindness by 2020

In 2013, World Health Assembly adopted the universal Eye Health: Global Action Plan 2014-19 to reduce the prevalence of avoidable visual impairment by 25% by 2019 compared to the baseline prevalence in 2010.

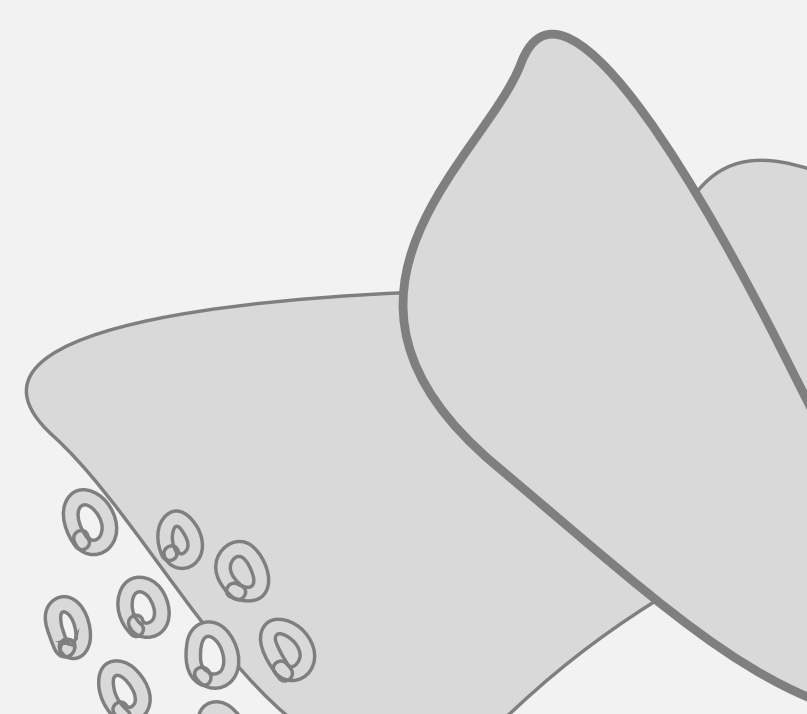
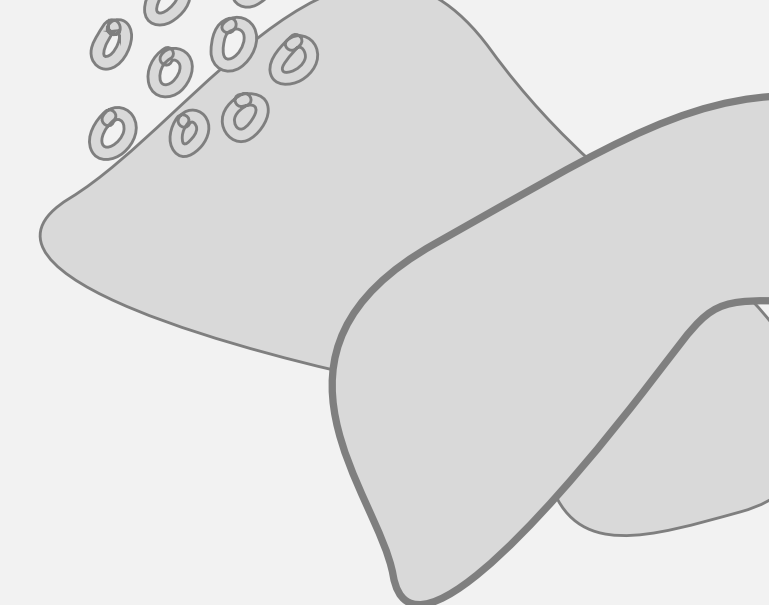


The Training Manual on Eye Care for Medical Officers builds on existing knowledge & skills by providing new information & skills. This includes the following contents:





OVERVIEW OF ANATOMY OF HUMAN EYE





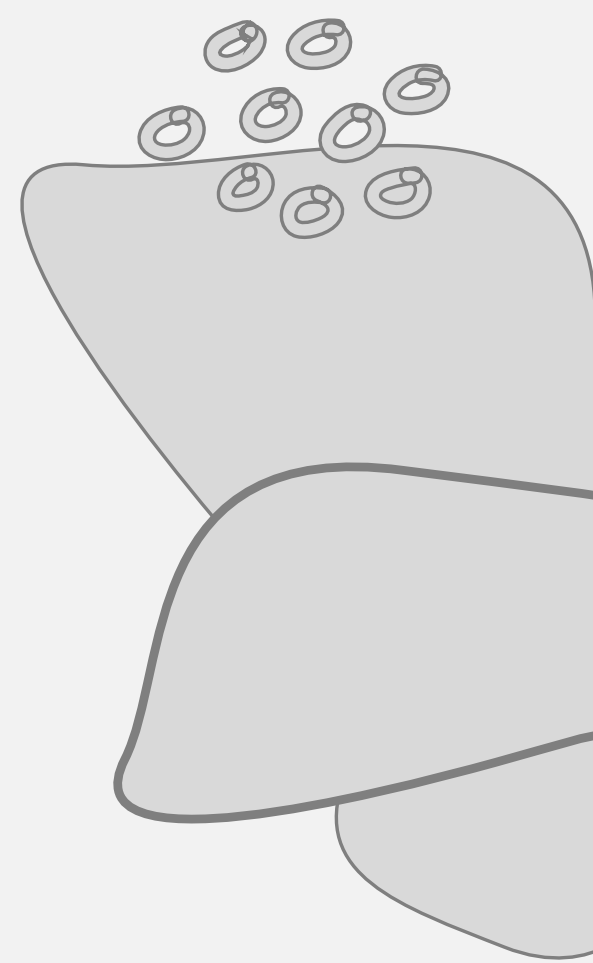THE EYE HAS

Three different layers:

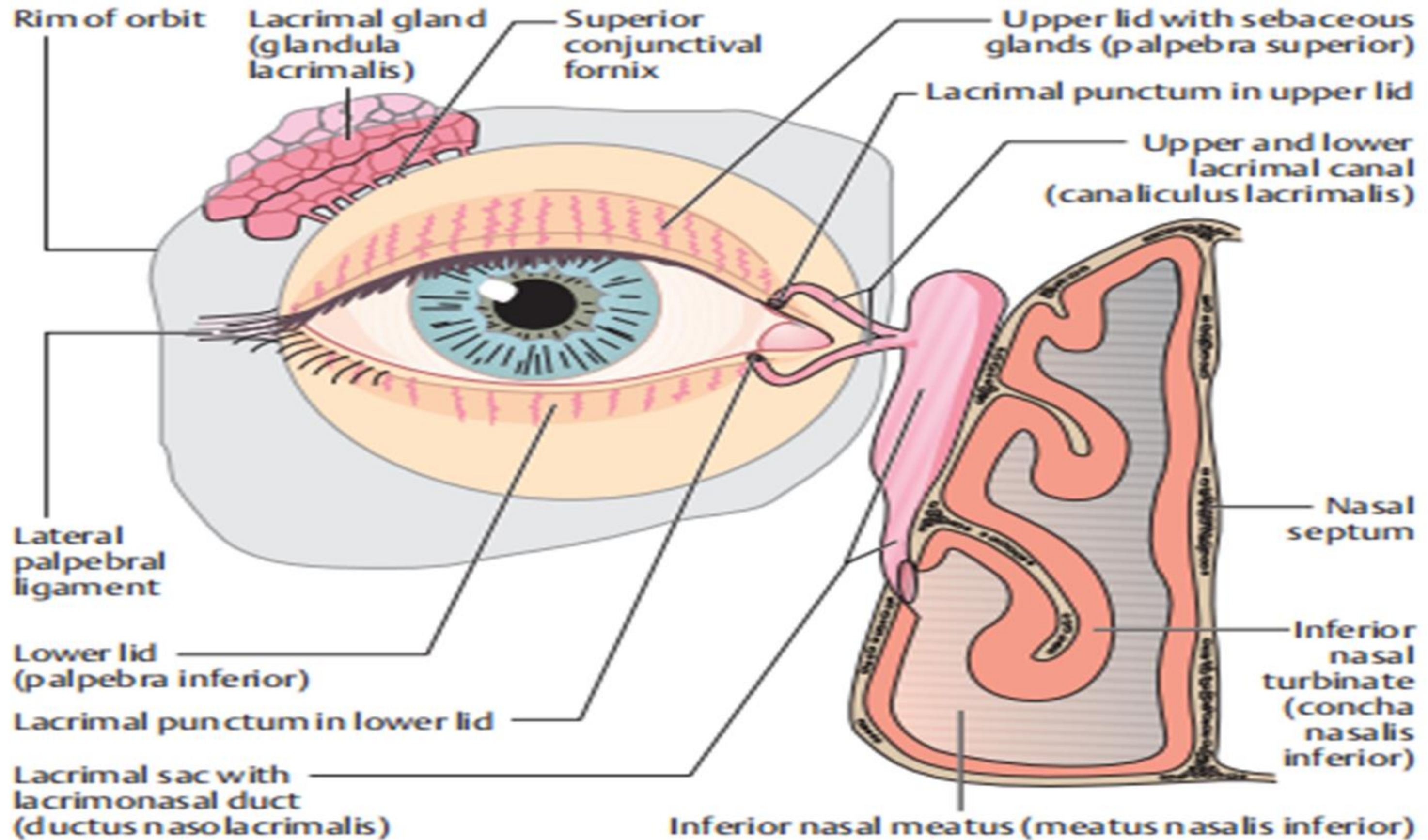
- The external layer, formed by the sclera and cornea;
- The intermediate layer, is divided into two parts: anterior (iris & ciliary body) & posterior (choroid);
- The internal layer, or the sensory part of the eye, the retina;

Three chambers of fluid:

- Anterior chamber (between cornea and iris)
- Posterior chamber (between iris, zonule fibers, and lens)
- The vitreous chamber (between the lens and the retina)



LACRIMAL APPARATUS

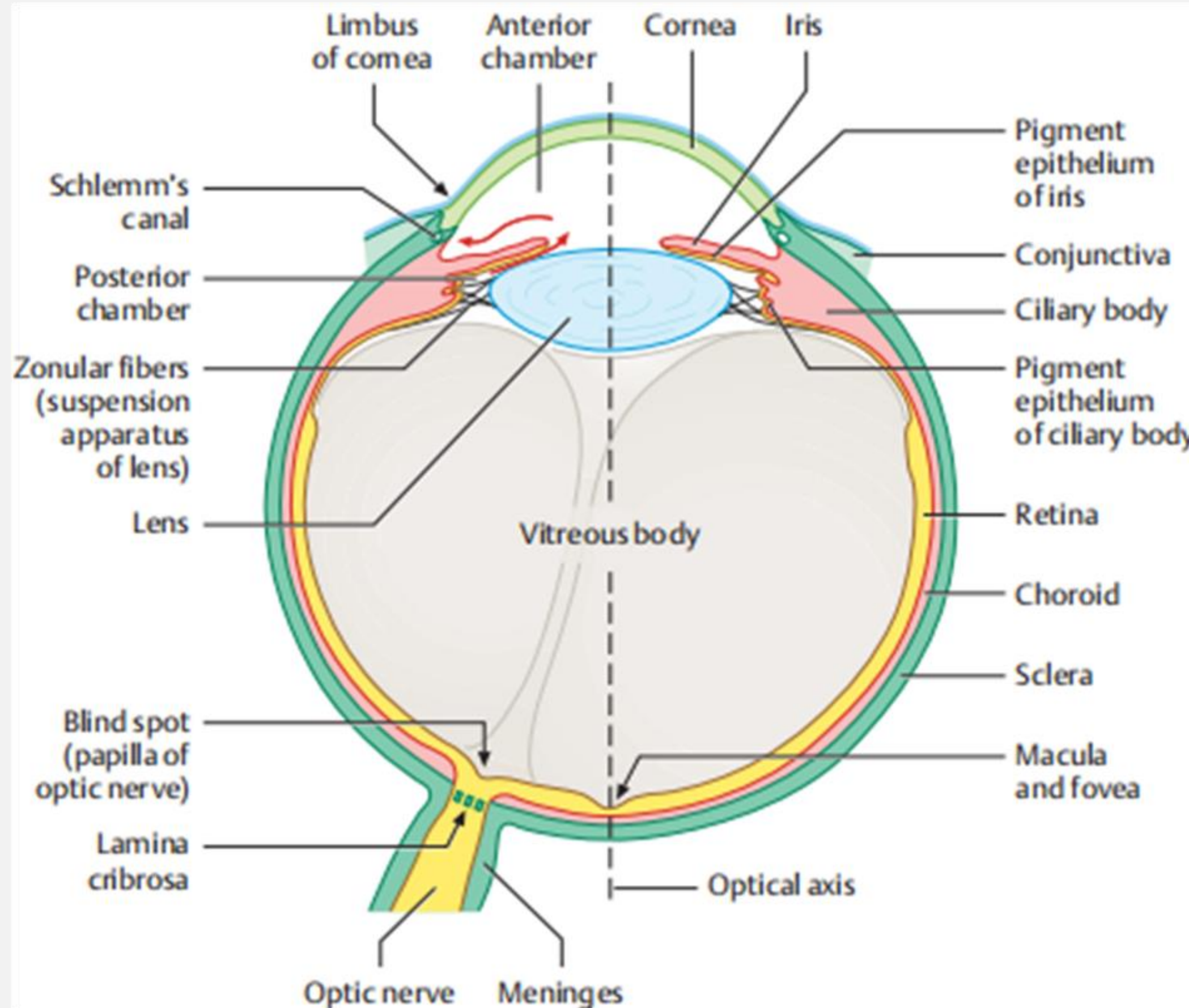




- The Sclera, the “white of the eye”, forms part of the supporting wall of the eyeball. The sclera is continuous with the cornea. This external covering of the eye is in continuity with the dura of the central nervous system. A transparent external surface, the Cornea, sits like a dome in the anterior 1/5th of the globe. The pupil and the iris can be seen through the Cornea. This is the first and most powerful lens of the optical system of the eye and allows, together with the crystalline lens, the production of a sharp image at the retinal photoreceptor level;
- A black-looking aperture, the pupil, allows light to enter the eye. The pupil is a central aperture in the colored circular muscles, the iris, which is pigmented and gives us our eye color. This circular muscle (iris) controls the size of the pupil so that more or less light, depending on conditions, is allowed to enter the eye;
- The lens is a transparent body located behind the iris. It is suspended by ligaments (called zonule fibers) attached to the anterior portion of the ciliary body. The contraction or relaxation of these ligaments, as a consequence of ciliary muscle actions, changes the shape of the lens, a process called accommodation that allows forming a sharp image on the retina;



HORIZONTAL SECTION OF EYEBALL



Source: Training Manual on Eye Care for Medical Officer at Ayushman Bharat-Health and Wellness Centres





- Light rays are focused through the transparent cornea and lens upon the retina. The central point for image focus (the visual axis) in the human retina is the fovea. Here a maximally focused image initiates resolution of the finest detail and direct transmission of that detail to the brain for the higher operations needed for perception. The optic axis is slightly closer to the nasal area and projects closer to the optic nerve head. The optic axis is the longest sagittal distance between the front or vertex of the cornea and the furthest posterior part of the eyeball. The eye is rotated around the optic axis by the extraocular muscles;
- Each eyeball is held in position in the orbital cavity by various ligaments, muscles, and fascial expansions that surround it. Three pairs of muscles (six muscles altogether) called Extra Ocular Muscles are inserted into the sclera. Two pairs of recti muscles run straight to the bony orbit of the skull and are orthogonal to each other (the superior rectus, the inferior rectus, the lateral rectus, and the medial rectus muscles). Another pair of muscles are the oblique muscles (superior oblique and inferior oblique). These extraocular muscles, in coordination, rotate the eyeball in the orbits and allow the image to be focused, at all times, on the fovea of the central retina;





Thank You

